International Journal of Pharmacology and Toxicology, 12 (1) (2024) 17-26

International Journal of Pharmacology and Toxicology

Website: www.sciencepubco.com/index.php/IJPT

Research paper

Acute toxicity: a comparative study on the methanol extract of three selected plants reported to have anticancer properties

Oladipo Miriam Oluchi [1], Oladipo Bamidele Fatai [2], Nwankwo Henry Chukwuebuka [1] *, Bosha Joel A [1], Saganuwan Alhaji Saganuwan [1], Onyeyili Patrick Azubuike [1]

[1] *Department of Veterinary Pharmacology and Toxicology, Joseph Sarwuan Tarka University, Makurdi, Benue state, Nigeria*
[2] *Del Scan Services Limited. 12th, 7th Avenue off Inikpi Street, High Level, Makurdi, Benue State, Nigeria*
**Corresponding author E-mail: nwankwo.henry@uam.edu.ng*

Abstract

Background: An acute toxicity study evaluates the harmful effects of substances absorbed through any route and utilizes parameters like LD50 to assess toxicity. While mortality is commonly used as a primary endpoint, considering signs of toxicity is crucial as they indicate adverse effects on internal organs, which can lead to lasting damage or death.
Objectives: This study compares the acute toxicity of three medicinal plants with anticancer properties, highlighting the importance of understanding their safety profiles despite their therapeutic potential.
Methods: The acute toxicity of methanol extracts from Curcuma longa rhizome, Datura metel fruits, and Phoenix dactylifera fruits in rats were compared to determine the safest of the three plant extracts. A new modified method was employed to estimate the Lowest Observed Adverse Effect Level (LOAEL) and the No Observed Adverse Effect Level (NOAEL). Each dose level involved three (3) rats, with a default dose progression of log 3.2 if the animal dies or a sign of toxicity is observed.
Results: While no mortality occurred at a dose of 5000 mg/kg body weight for any extract, signs of toxicity were observed. Histological changes were noted in animals without apparent signs of toxicity, challenging the assumption that LD50 values exceeding 5000 mg/kg body weight indicate non-toxicity. Threshold dose analysis revealed differences in toxicity among the extracts. Curcuma longa rhizome methanol extract demonstrated the highest safety margin.
Conclusion: These findings emphasize the importance of considering signs of toxicity alongside mortality in acute toxicity assessments.

Keywords: *Acute Toxicity; Lethal Median Dose (LD50); Curcuma Longa; Datura Metel; Phoenix Dactylifera.*

1. Introduction

An acute toxicity study is a brief evaluation of the harmful effects of a substance absorbed through any exposure route [1] . It serves to screen plants, gather data on a chemical's biological activity, evaluate the safety of a substance, and understand how pharmacological agents affect toxicity [2]. Acute toxicity study is measured using specific parameters such as median lethal dose (LD_{50}), toxic dose, threshold dose, etc. The LD_{50} is commonly employed in measuring acute toxicity. The limit test, the fixed-dose procedure [3], the acute toxic class (ATC) method [4], and the up-and-down procedure [3], [5] all represent simplified alternatives to assessing LD_{50} [1]. The Fixed Dose Procedure (FDP), introduced in 1992, provides insights into toxicity by considering non-lethal endpoints, facilitating better understanding of recovery from toxicity upon toxicant removal [1]. In the evaluation of acute toxicity, mortality is commonly used as a primary endpoint, but it's crucial to also consider signs of toxicity since they indicate adverse effects on the body's organs [6 - 8]. The severity of toxicity should be prioritized over mortality alone, as certain substances may cause harm without necessarily leading to death, instead causing biochemical or structural changes in internal organs that can result in lasting damage or eventual death [9]. Medicinal plants have played a fundamental role in healthcare since ancient times and continue to be highly valued in today's global trade. Both edible plants like Curcuma longa Linn and Phoenix dactylifera, and non-edible ones like Datura metel, are widely embraced by the public as safe and effective alternatives to conventional medical treatments for various ailments [10] (Ozioma and Chinwe, 2019). These plants have been recognized for their potential to combat cancer, enhance the production of antioxidant enzymes, and modulate cellular signaling pathways [11], [12]. The challenge of chemotherapy's effectiveness and success lies in its toxicity to healthy body tissues [13].
A comparative acute toxicity study of three plants (Curcuma longa Linn rhizome, Datura metel fruits and Phoenix dactylifera fruits) reported to have anti-cancer properties [14 - 20] was carried out in this study. Comparative studies assessing the acute toxicity of the three plants, all noted for their anticancer properties, have not been previously documented.

Copyright © Oladipo Miriam Oluchi et al. This is an open access article distributed under the Creative Commons Attribution License, which permits unrestricted use, distribution, and reproduction in any medium, provided the original work is properly cited.

2. Materials and methods

2.1. Experimental animals

Albino Wistar rats (Rattus norvegicus) were used for all the in-vivo studies. Breeding rats were sourced from local breeders in Makurdi, Benue state, Nigeria, and kept in plastic cages and were kept in a room maintained at 25±2ºC with a 12h light/dark cycle. The animals used for all the experiments were bred and allowed to attain maturity (8 to 12 weeks old) before they were employed for the experiment. Apparently healthy, young adult, non-pregnant female rats weighing 110 - 140g were used for the study. They were fed with standard feeds (Chikun grower(R) pellet) and water was provided ad libitum. The experiments were conducted according to international guiding principles for biomedical research involving animals [21], and as recommended by the ethical committee of the College of Veterinary Medicine, Joseph Sarwuan Tarka University, Makurdi; with designated ethical clearance reference number JOSTUM/CVM/ETHICS/2023(2).

2.2. Plant collection, identification and extraction

The rhizomes of Curcuma longa Linn and the fruits of Phoenix dactylifera were purchased from local traders at the Wadata market, Makurdi, Benue state, Nigeria, while a branch of the Datura metel shrub containing the fruits and leaves was collected from a site at Northbank, Markurdi, Benue state; and submitted for confirmation and authentication by a plant taxonomist in the Department of Forestry, Joseph Sarwuan Tarka University, Makurdi. The rhizomes and fruits from different plants were air-dried under the shade (away from sunlight) separately and thereafter ground to a fine powder using a commercial miller. Maceration in 70% methanol was used to extract each plant material in a 1:10 ratio of plant matter to solvent [22]. The mixture was agitated occasionally for 48 hours; after that the supernatant of each plant material was filtered with 150MM Whatman No.1 filter paper into pre-weighed jars. The filtrate was dried under a stream of air at 45^0C after which the total dry masses were determined. The extract yield was collected into an air-tight container, labeled, and stored at 4^0C until use [23, 24]. The percentage of yield of the extract was calculated using the following formula:

$$\text{Percentage of yield} = \frac{\text{Final weight of dried extract}}{\text{Original weight of powder}} X\ 100$$

To identify a suitable solvent for the extracts utilized in the oral toxicity studies, various solvents were tested, including distilled water, tween-20, propylene glycol, groundnut oil, tween 80, and DMSO. The methanol plant extracts were prepared at a concentration of 500mg/ml for the experiment.

2.3. Acute toxicity study/Limit dose test

The upper limit dose test was adopted to estimate the median lethal dose (LD_{50}) of the methanol extract of Curcuma longa Linn rhizome, Datura metel, and Phoenix dactylifera fruits following OECD guidelines. A new modified method was employed to estimate the Lowest Observed Adverse Effect Level (LOAEL) and the No Observed Adverse Effect Level (NOAEL). Each dose level involved three (3) rats, with a default dose progression of log 3.2 if the animal dies or a sign of toxicity is observed [3, 6, 25, and 26]. The initial dose of 5000 mg/kg/day of all test materials were administered, followed by subsequent doses of 3415, and 1830 mg/kg/day, while monitoring for signs of toxicity, behavioural alteration and mortality. Each animal was observed for 1 or 2 days prior to administration of the next animal, rats that survived were observed for clinical signs over a two-week period post-administration. Testing was completed after initial reversal in animal outcome and was also terminated when a dosage level per kg body weight was attained without mortality or signs of toxicity following protocols outlined by Bruce [27] and OECD 425 [4] incorporating an element of OECD 420 [4]. Rats were euthanized after two weeks using 100mg/kg/day of pentobarbital [28]. Gross post-mortem examination was conducted on all animals at the experiment's conclusion. The NOAEL for each test material was determined as the dose level where no signs of toxicity were observed in two consecutive exposures, while the LOAEL was calculated using the same method employed by Saganuwan [30] for the rough estimation of median lethal dose.

2.4. Histopathological evaluation

All the animals that had no observable signs of toxicity were euthanized after two weeks of observation. Tissue samples (heart, lungs, spleen, kidney and liver) were harvested and fixed in 10% formalin. The tissue was dehydrated through graded concentrations of ethanol (70%, 95% and 100%), then cleared in xylene and embedded in paraffin wax. The embedded tissues were stained with Hematoxylene (1^0 dye) and Eosin (2^0 dye) (H & E) and observed under a light microscope with x400 magnification [30]. Any lesion observed on the sections was photographed using Magnus Digital Pad Microscope Camera. All the tissue slides were examined blindly, and the occurrence of lesions in organs was assessed according to the methodology proposed by Giordani [31].

3. Result

The percentage yield of the methanol extract of Curcuma longa Linn rhizome, Datura metel, and Phoenix dactylifera fruits were 12.7, 14.9, and 56.35% respectively.

3.1. Acute toxicity response to different doses of curcuma longa linn rhizome, datura metel fruits, and phoenix dactylifera fruits

There was no mortality nor observed signs of toxicity in the rats administered 5000mg/kg BW of the methanol extract of Curcuma longa rhizome in three (3) consecutive administrations (Table 1 and 2), whereas signs of toxicity were observed in all three (3) consecutive administrations of 5000mg/kg BW of the methanol extract of Datura metel and Phoenix dactylifera fruits; however, one (1) mortality was recorded with Phoenix dactylifera at this dose level (Table 1). No deaths occurred when the dose was reduced by a factor of 3.2 to 3415

mg/kg body weight for both Datura metel and Phoenix dactylifera. Two consecutive administrations of Datura metel at the 3415 mg/kg dose level showed signs of toxicity, whereas only one instance of toxicity was observed at the 1830 mg/kg dose level for Datura metel, as depicted in Table (1). Notably, unstable motor activity, anaesthesia, Straub reaction, hyperesthesia, and blanching were observed in rats given 5000 mg/kg BW of Phoenix dactylifera on day 1, with death occurring within 2 minutes at this dose. Tremors were observed on day 7 with 3415 mg/kg BW of Datura metel, while arching, rolling, tonic extension, and breathlessness were noted at 5000 mg/kg BW of both Datura metel and Phoenix dactylifera. Sedation was observed at day 1 with 5000 mg/kg BW of Datura metel and Phoenix dactylifera, and on day 7 with 3415 mg/kg BW of Datura metel. Stimulation was noted after 1 and 6 hours of administration of 5000 mg/kg BW of Phoenix dactylifera. However, no signs of toxicity were observed in all the rats administered 5000 mg/kg BW of Curcuma longa rhizome. Similarly, among the rats given Datura metel, two rats at the dosage of 1830 mg/kg BW and one rat at 3415 mg/kg BW showed no signs of toxicity. Additionally, in the case of Phoenix dactylifera, one rat administered 3415 mg/kg BW did not exhibit any signs of toxicity. Toxicity reversal was observed in one rat administered 5000 mg/kg BW of Datura metel after day 7 (Table 2).

3.2. Gross pathology report of animals administered different doses of curcuma longa linn rhizome, datura metel fruits, and phoenix dactylifera fruits

The gross pathologic lesions of the animals to which the plant extracts were administered showed marked features differing from those of the control animal (Figure 1: C1).

Heart: The post-mortem picture reveals that the heart was intact (no visible change) in all the animals administered except that there was mild congestion in the animal administered 5000 mg/kg body weight of Datura metel (table 3; Figure 1: DM1). As represented in table (1) and (2), there was no sign of toxicity observed in the animals administered 5000mg/kg body weight of Curcuma longa, however, the heart was shrunken in one animal (Figure 1: CL1) but the gross picture of the heart was normal in two subsequent administrations (Figure 1: CL2).

Liver: The gross pictures of the liver showed mild to moderate congestion in most of the animals except those administered 3415 (Figure 1: PD2), 5000 (Figure 1: CL2) and 5000 (Figure 1: PD1) mg/kg body weight of methanol extract of Phoenix dactylifera, Curcuma longa and Phoenix dactylifera respectively which showed no visible lesions (table 3).

Spleen and Kidney: Most of the spleens and kidneys also had mild to moderate congestions and those with no visible lesions in both organs were those administered 1830, 3415, and 5000 mg/kg body weight of D. metel (Figure 1: DM3), P. dactylifera (Figure 1: PD2), and Curcuma longa (Figure 1: CL2) respectively (table 3).

Lungs: The gross pictures of the lung showed varying degrees of haemorrhage ranging from pin-point to generalized haemorrhages (Figure 1: PD1, DM3, D2 and CL1), congestion of the caudal lobes (Figure 1: CL1), lobular collapse (Figure 1: DM1 and DM2) and pale appearance (Figure 1: DM2, CL2, PD1 and PD2). Zones of necrosis were visualized on certain lung tissues (Figure 1: DM3 and PD1) and as described in table (3) and illustrated in Figure (1).

3.3. Histology report of excised organs from animals with no observable signs of toxicity when administered different doses of methanol extract of curcuma longa linn rhizome, datura metel fruits, and phoenix dactylifera fruits

Heart: Figure (2) shows 2 shows histology sections of the heart tissue of control rat (a) and rats administered 5000 mg/kg BW Curcuma longa (b), 1830 mg/kg BW Datura metel (c), and 3415 mg/kg BW of Phoenix dactylifera (d) respectively. The control heart tissue (Figure 2: a) exhibited a typical architecture with no pathology observed. A Rat administered 5000 mg/kg BW of Curcuma longa (Figure 2: b) displayed similar cardiac morphology to the control group, with no signs of toxicity. In contrast, a rat given 1830 mg/kg BW of Datura metel (Figure 2: c) showed mild cardiac toxicity, characterized by muscular nuclei enlargement and intermuscular connective tissue fibrocytes increase. That administered 3415 mg/kg BW of Datura metel displayed similar toxicity, with additional features of muscle fiber destruction and thickened muscle fibers. The most significant cardiac toxicity was observed in a rat given 5000 mg/kg BW of Datura metel, showing congested vessels, vascular dilation, and intermuscular extravasation of red blood cells. Similarly, a rat administered 5000 mg/kg BW of Phoenix dactylifera (Figure 2: d) exhibited mild cardiac toxicity, with intermuscular spacing increase and vascular dilation. However, no observable signs of toxicity were noted in a rat given 3415 mg/kg BW of Phoenix dactylifera.

Lungs: The histology sections of lung tissue in Figure (3) shows that of a control rat (a) and animals administered 5000 mg/kg BW Curcuma longa (b), 1830 mg/kg BW Datura metel (c), and 3415 mg/kg BW of Phoenix dactylifera (d) respectively. The control lung tissue (Figure 3: a) displayed a typical respiratory architecture with no pathological features. A rat given 5000 mg/kg BW of Curcuma longa (Figure 3: b) exhibited mild pulmonary toxicity, characterized by empty alveoli sacs, presence of alveolar macrophages and pneumocytes, and red blood cells in capillaries. In contrast, a rat administered 1830 mg/kg BW of Datura metel (Figure 3: c) showed signs of acute pneumonia, including lesions in the alveolar stroma, dilatation of terminal bronchioles, and presence of inflammatory cell infiltrates. However, no signs of toxicity were observed at this dose level. Higher doses of Datura metel (3415 and 5000 mg/kg BW) resulted in more severe pulmonary reactions indicative of mild pulmonary vascular reactions and severe pulmonary toxicity, accompanied by visible signs of toxicity and significant gross morphological abnormalities. On the other hand, a rat administered 3415 mg/kg BW of Phoenix dactylifera (Figure 3: d) showed minimal respiratory changes compared to the control group, with only mild vascular congestion and dilation observed. Although no signs of toxicity were noted, the lung tissues exhibited slight distortion in the capillary beds of interstitial connection.

Liver: The liver histology sections of a control rat (a) and rats administered 5000 mg/kg BW Curcuma longa (b), 1830 mg/kg BW Datura metel (c), and 3415 mg/kg BW of Phoenix dactylifera (d) respectively are represented in Figure (4). The control liver section (Figure 4: a) displayed typical hepatic architecture with no pathological findings. A rat given 5000 mg/kg BW of Curcuma longa (Figure 4: b) exhibited hepatic toxicity, characterized by nuclei condensation, fragmentation of hepatic plate cells, and vacuolated cytoplasm. Similarly, a rat administered 1830 mg/kg BW of Datura metel (Figure 4: c) showed signs of hepatic toxicity, including congestion of central veins, periductal destruction, and interlobular vessel dilation. The severity of hepatic toxicity increased with dose, observed also in rats given 3415 and 5000 mg/kg BW of Datura metel. Conversely, a rat administered 3415 mg/kg BW of Phoenix dactylifera (Figure 4: d) showed mild hepatic toxicity, indicated by constricted central veins and sinusoidal spaces, without observable signs of toxicity. However, the severity of hepatic toxicity correlated with the dose administered, with marked toxicity observed at 5000 mg/kg BW.

Kidneys: Figure (5) shows histology sections of kidney tissue of a control rat (a) and rats administered 5000 mg/kg BW Curcuma longa (b), 1830 mg/kg BW Datura metel (c), and 3415 mg/kg BW of Phoenix dactylifera (d) respectively. The control kidney section (Figure 5: a) exhibited typical renal architecture without pathology. A rat given 5000 mg/kg BW of Curcuma longa (Figure 5: b) showed renal toxicity, characterized by distorted glomeruli, increased capsular spaces, and tubular congestion. Similarly, a rat administered 1830 mg/kg

BW of Datura metel (Figure 5: c) displayed mild renal toxicity, evidenced by renal corpuscle expansion and tubular degeneration. The severity of renal toxicity increased with dose, observed in rats given 3415 and 5000 mg/kg BW of Datura metel, with marked destruction of renal architecture. Conversely, a rat administered 3415 mg/kg BW of Phoenix dactylifera (Figure 5: d) exhibited mild renal toxicity, indicated by renal corpuscle constriction and tubular distortion, with no observed signs of toxicity. However, at 5000 mg/kg BW, marked renal toxicity was evident; correlating with mildly congested renal tissue.

Spleen: The histology sections of spleen tissue of a control rat (a) and rats administered 5000 mg/kg BW Curcuma longa (b), 1830 mg/kg BW Datura metel (c), and 3415 mg/kg BW of Phoenix dactylifera (d) respectively are represented in Figure (6). The control spleen section (Figure 6: a) exhibited typical architecture with diffuse cellular lymphoid tissue and variable-sized lymphoid nodules. The rat given 5000 mg/kg BW of Curcuma longa (Figure 6: b) showed distorted lymphoid nodules, dilated central arteries, and disorganized splenic cords, suggestive of reactive lymphoid tissue. In contrast, the rat administered 1830 mg/kg BW of Datura metel (Figure 6: c) displayed lymphoid hyperplasia with distorted lymphoid nodules and increased leukocyte bands. Similar features were observed in rats given 3415 and 5000 mg/kg BW of Datura metel, indicating moderate vascular aberrations and lymphoid nodule picture consistent with the lower dose (1830 mg/kg BW). For Phoenix dactylifera, the rat administered 3415 mg/kg BW (Figure 6: d) exhibited slight systemic toxicity, characterized by congested vessels and increased cellular components, while the rat given 5000 mg/kg BW showed more severe systemic toxicity, although the gross picture remained normal. Overall, histopathological findings were consistent with gross morphology observations and toxicity profiles outlined in Tables (1), (2) and (3).

4. Discussion

The methanol extracts from Curcuma longa rhizome, and Datura metel fruit were found to be completely soluble in Tween 80. This indicates that Tween 80 was an effective solvent for dissolving these extracts, allowing the formation of homogeneous solutions for further experimentation. Given that the methanol extracts dissolved completely in Tween 80, it was chosen as the solvent for the extracts in the acute toxicity studies. The complete solubility ensured that the extracts could be accurately dosed and administered in a consistent manner during the toxicity assessments. The choice of solvents and vehicles is also critical, considering their safety profiles and compatibility with the biological system under investigation [32], [33].

Acute toxicity assessments are vital in toxicological studies, encompassing mortality, biological effects, and adverse reactions from substance exposure [34]. The safety of any substance that causes clinical signs of toxicity upon exposure via any route is uncertain [35]. This study observed subtle histological changes in animals exposed to doses of 5000, 1830, and 3415 mg/kg body weight of methanol extract from Curcuma longa, Datura metel, and Phoenix dactylifera, respectively, despite no apparent signs of toxicity. These histological changes correlated strongly with gross morphology examination, indicating adverse effects. The findings challenge Hodge and Sterner's [36] toxicity scale, suggesting that compounds with an oral LD_{50} exceeding 5000 mg/kg body weight in rats are essentially non-toxic. Additionally, they align with Saganuwan's (2017) [26] report, which emphasizes observable signs of toxicity as relevant endpoints for LD_{50} determination, also putting animal welfare into consideration. Administration of 5000 mg/kg body weight of methanol extract of Curcuma longa rhizome, Datura metel, and Phoenix dactylifera fruits did not result in mortality, indicating LD_{50} values exceeding 5000 mg/kg body weight, classifying these extracts as non-toxic. However, signs of toxicity were noted. This aligns with the idea that certain substances, while not lethal, can induce changes in biochemical or cytostructural aspects of internal organs, potentially leading to lasting harm or eventual death (Miller and Zachary, 2017) [9]. The histological changes observed in animals without apparent toxicity suggest that LD_{50} values for these plant extracts should not be assumed to be >5000 mg/kg body weight.

A threshold dose (NOAEL and LOAEL) is more pertinent than a Lethal Dose (LD_{50}) when determining the appropriate dosage for a substance, particularly for long-term administration as in cancer chemotherapy. The threshold dose represents the level below which no observable response occurs, ensuring a zero probability of individual response [37, 38]. It is crucial for evaluating the safe dosage for chronic exposure, assuming the existence of a safety margin where no adverse biological effects are anticipated [39]. A rat administered 5000 mg/kg BW of methanol extract of Phoenix dactylifera fruit died amounting to a mortality rate of 20%, while no mortality was observed in those given methanol extract of Curcuma longa rhizome and Datura metel fruit. However, 60% of the rats administered Phoenix dactylifera methanol fruit extract showed signs of toxicity, compared to 66.7% of the rats administered Datura metel methanol fruit extract. As determined, the LD_{50} of methanol extract for Curcuma longa rhizome, Datura metel and Phoenix dactylifera fruit is >5000 mg/kg BW. However the LOAEL values are 5000 ± 00, 2622.5 ± 792.5, and 4207.5 ± 792.5 (mean ± SEM) mg/kg BW, respectively, with corresponding NOAEL values of less than 5000, 1830, and 3415 mg/kg BW. The default dose progression for methanol fruit extracts of Datura metel and Phoenix dactylifera is log 3.05. Tissue examinations of animals without observable toxicity revealed slight changes compared to those with evident toxicity but no fatalities. Despite all three methanol plant extracts having LD_{50} values exceeding 5000 mg/kg BW, their threshold values differ, indicating that methanol extract of Datura metel fruit has the lowest threshold dose and is more toxic than Phoenix dactylifera methanol fruit extract, followed by Curcuma longa rhizome extract. Hence, if Datura metel methanol fruit extract is to be administered over an extended period, it should be at a lower dose than methanol extract of Phoenix dactylifera fruit and Curcuma longa rhizome. This study highlights methanol extract of Curcuma longa rhizome as the safest among the three methanol plant extracts, despite sharing the same LD50 value.

5. Conclusion

This study evaluates the acute toxicity of methanol extracts from Curcuma longa rhizome, Datura metel fruits, and Phoenix dactylifera fruits in rats. While no mortality occurred at a dose of 5000 mg/kg body weight for any extract, signs of toxicity were observed. Histological changes were noted in animals without apparent toxicity, challenging the assumption that LD_{50} values exceeding 5000 mg/kg body weight indicate non-toxicity. Threshold dose analysis revealed differences in toxicity among the extracts. Curcuma longa rhizome methanol extract demonstrated the highest safety margin. These findings emphasize the importance of considering signs of toxicity alongside mortality in acute toxicity assessments.

Acknowledgments

The authors wish to sincerely acknowledge the supports of the staff of Delscan Laboratory services and the staff of the Department of Veterinary Pharmacology and Toxicology. The authors also wish to state that this work was fully self sponsored by the authors.

Table 1: A Representation of the Acute Toxicity Response of Rats to Different Doses of Curcuma Longa, Datura Metel, and Phoenix Dactylifera

	Curcuma longa		Datura metel		Phoenix dactylifera	
Dose (mg/kg BW)	Sign of toxicity	Mortality	Sign of toxicity	Mortality	Sign of toxicity	Mortality
5000	OOO	OOO	XXX	OOO	XXX	XOO
3415	----	----	XXO	OOO	OO	OO
1830	----	----	XOO	OOO	----	----

Key: X= present, O=absent

Table 2: Signs of Clinical Toxicity Observed in the Rats Administered Different Doses of the Methanol Extract of Curcuma Longa, Datura Metel, and Phoenix Dactylifera

Signs of toxicity	C. longa	Datura metel	Phoenix dactylifera
Unstable motor activity	NIL	NIL	Observed at day 1 of 5000mg/kg BW
Anaesthesia	NIL	NIL	Observed at day 1 of 5000mg/kg BW
Tremors	NIL	Observed at day 7 of 3415mg/kg	NIL
Arching and rolling	NIL	Observed at day 7 of 3415mg/kg	Observed 2 minutes after administration of 5000mg/kg BW
Tonic extension	NIL	Observed at day 1 of 5000mg/kg BW	Observed at day 1 of 5000mg/kg BW
Straub reaction	NIL	NIL	Observed at day 1 of 5000mg/kg BW
Hyperesthesia	NIL	NIL	Observed at day 1 of 5000mg/kg BW
Stimulation	NIL	NIL	Observed after 1 and 6 hours of 5000mg/kg BW respectively
Sedation	NIL	Observed at day 7 and 1 of 3415 and 5000mg/kg BW respectively	Observed at day 1 of 5000mg/kg BW
Blanching	NIL	NIL	Observed at day 1 of 5000mg/kg BW
Partial paralysis	NIL	NIL	Observed at day 1 of 5000mg/kg BW
Breathlessness and gasping	NIL	Observed at day 1 of 5000 mg/kg BW	Observed at day 1 of 5000mg/kg BW
Death	NIL	NIL	Observed within 2 minutes of 5000 mg/kg BW
No signs of toxicity	At 5000 mg/kg BW	At 1830 and 3415 mg/kg BW	At 3415 mg/kg BW
TOXICITY REVER-SAL	NIL	Observed after day 7 of 5000 mg/kg BW	NIL

*BW = body weight

Table 3: Description of the Gross Post-Mortem Morphology Observed in the Rats Administered Different Doses of the Methanol Extract of Curcuma Longa, Datura Metel, and Phoenix Dactylifera

		Organs				
Plant extracts (concen-tration in mg/ml)	Dose (mg/kg bw)	Lungs	Heart	Liver	Spleen	Kidney
Curcuma longa (500)	5000 (ref* CL1)	Diffused haemorrhages of the caudal lobes, Slightly enlarged	Shrink	Moderately congested	Moderately congested	Moderately congested
	5000 (ref* CL2)	Pale	Normal	Normal	Normal	Normal
Datura metel (500)	5000	Collapsed right lung, Collapsed cranial lobe of the left lung	Mildly con-gested	Mildly congest-ed	Mildly congest-ed	Mildly congest-ed
	3415	Pale and collapsed	Normal	Mildly congest-ed	Mildly congest-ed	Mildly congest-ed
	1830	Pin point haemorrhages and areas of necrosis	Normal	Mildly congest-ed	Normal	Normal
Phoenix dactylifera (500)	5000	Pin point haemorrhages and areas of necrosis, Pale	Normal	Normal	Normal	Mildly congest-ed
	3415	Pale	Normal	Normal	Normal	Normal

* = referred to as

Fig. 1: Showing the various plant materials used for the experiment: *Datura metel; Curcuma longa; Phoenix dactylifera*

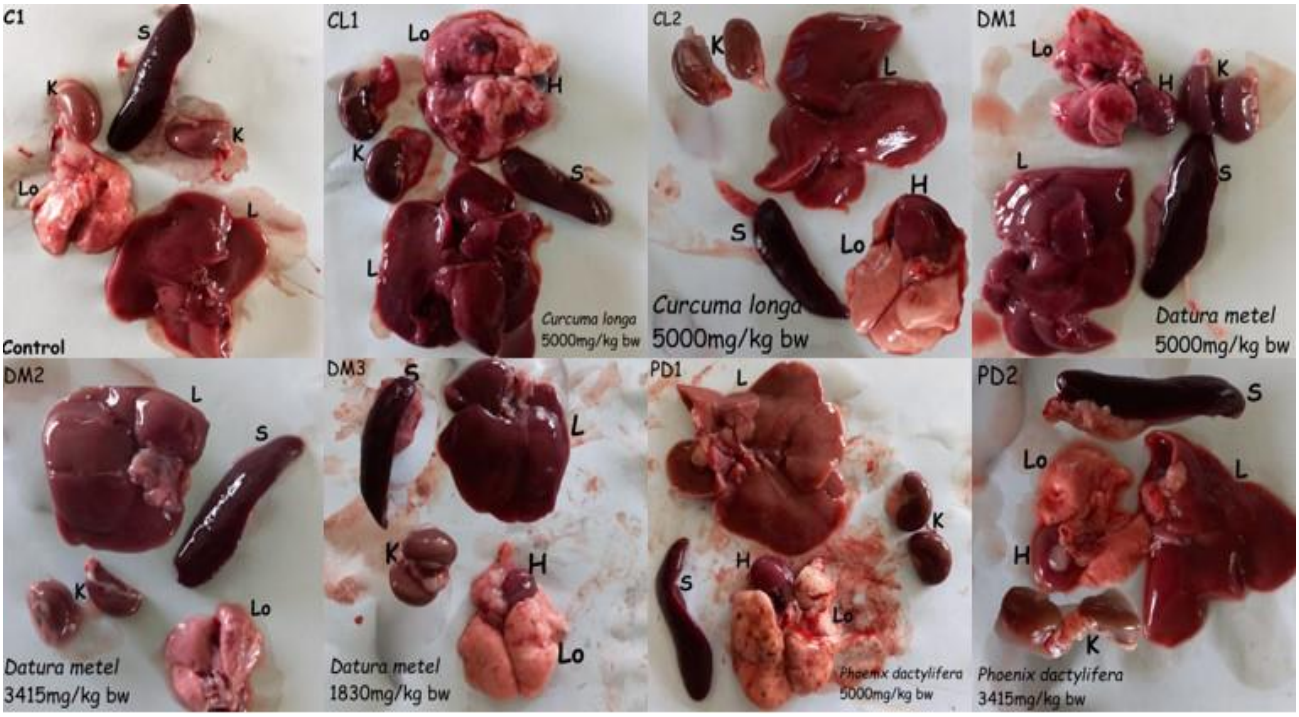

Fig. 2: Showing Post-Mortem Gross Pathology Picture.

Key: H = heart, K = kidneys, L = liver, Lo = lungs, S = spleen, BW = body weight

- Heart tissue sections

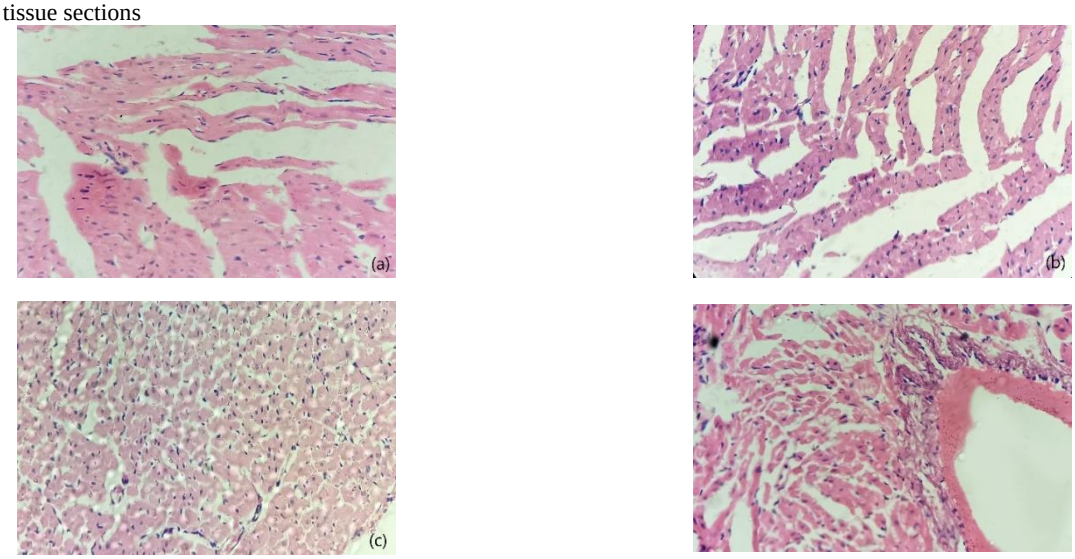

Fig. 3: Showing Histology Sections of Heart Tissue of Control Rats (A) and Rats Administered 5000 Mg/Kg BW Curcuma Longa (B), 1830 Mg/Kg BW Datura Metel (C) and 3415 Mg/Kg BW of Phoenix Dactylifera (D) Respectively.

- Lungs tissue sections

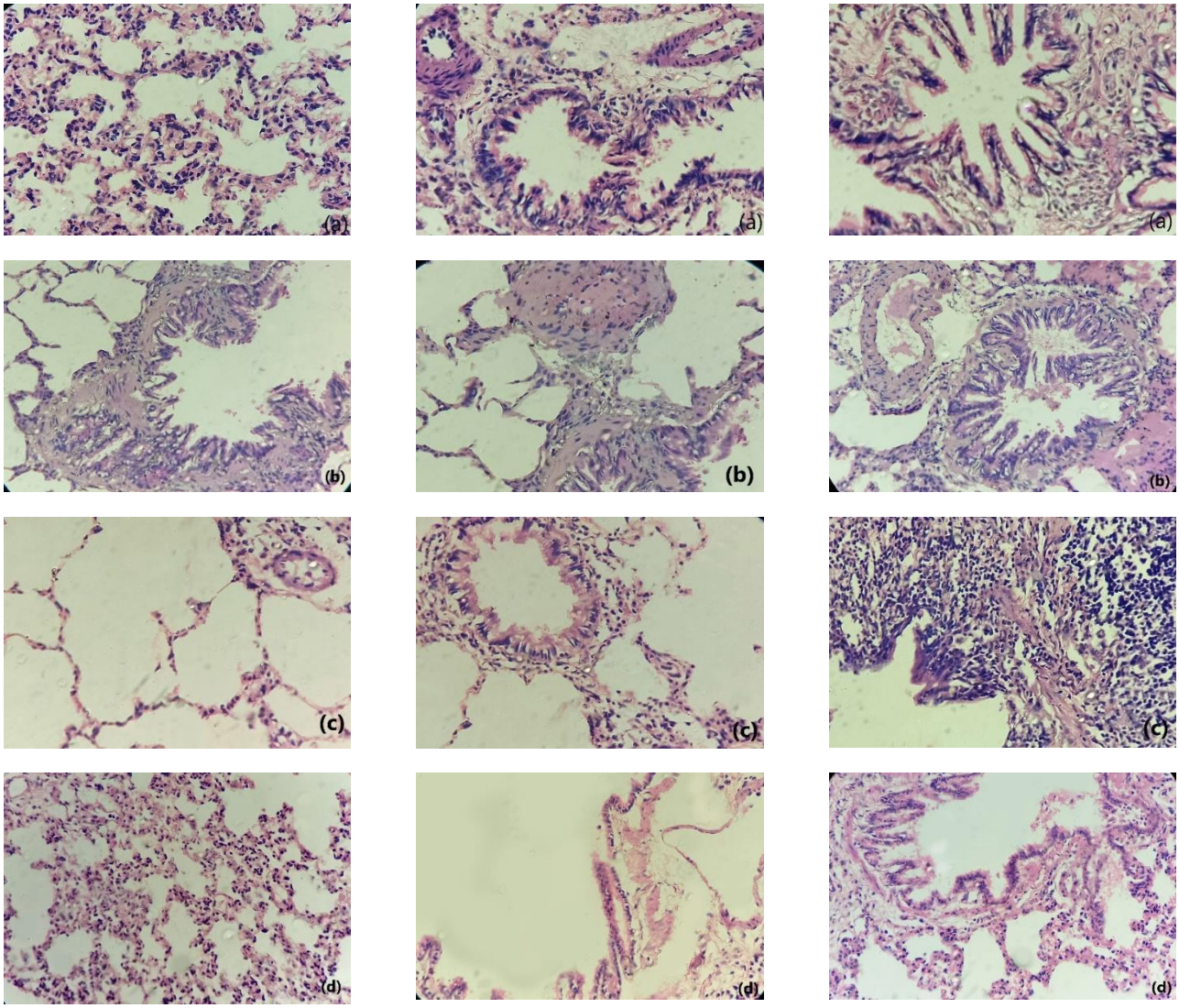

Fig. 4: Showing Histology Sections of Lung Tissue of Control Animals (A) and Animals Administered 5000 Mg/Kg BW Curcuma Longa (B), 1830 Mg/Kg BW Datura Metel (C) And 3415 Mg/Kg BW of Phoenix Dactylifera (D) Respectively.

- Liver tissue sections

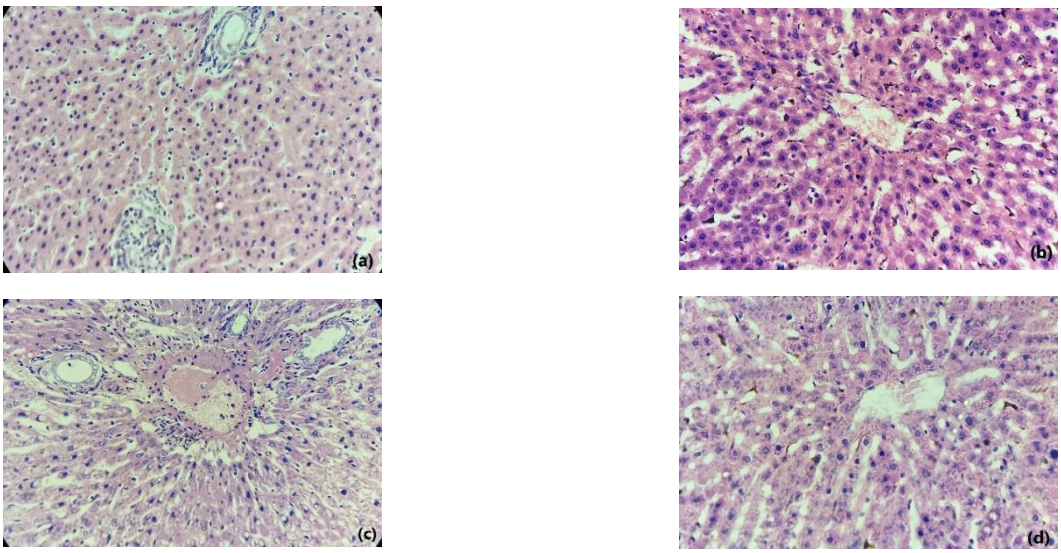

Fig. 5: Showing Histology Sections of Liver Tissue of Control Rats (A) and Rats Administered 5000 Mg/Kg BW Curcuma Longa (B), 1830 Mg/Kg BW Datura Metel (C) and 3415 Mg/Kg BW of Phoenix Dactylifera (D) Respectively.

- Kidney tissue sections

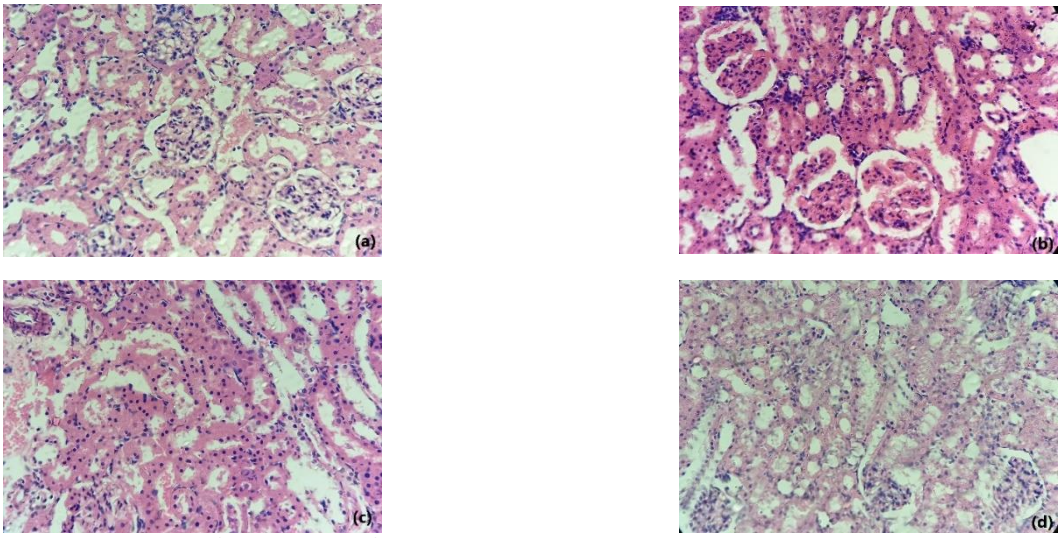

Plate. 1: Showing Histology Sections of Kidney Tissue of Control Rats (A) and Rats Administered 5000 Mg/Kg BW Curcuma Longa (B), 1830 Mg/Kg BW Datura Metel (C) and 3415 Mg/Kg BW of Phoenix Dactylifera (D) Respectively

Spleen tissue sections

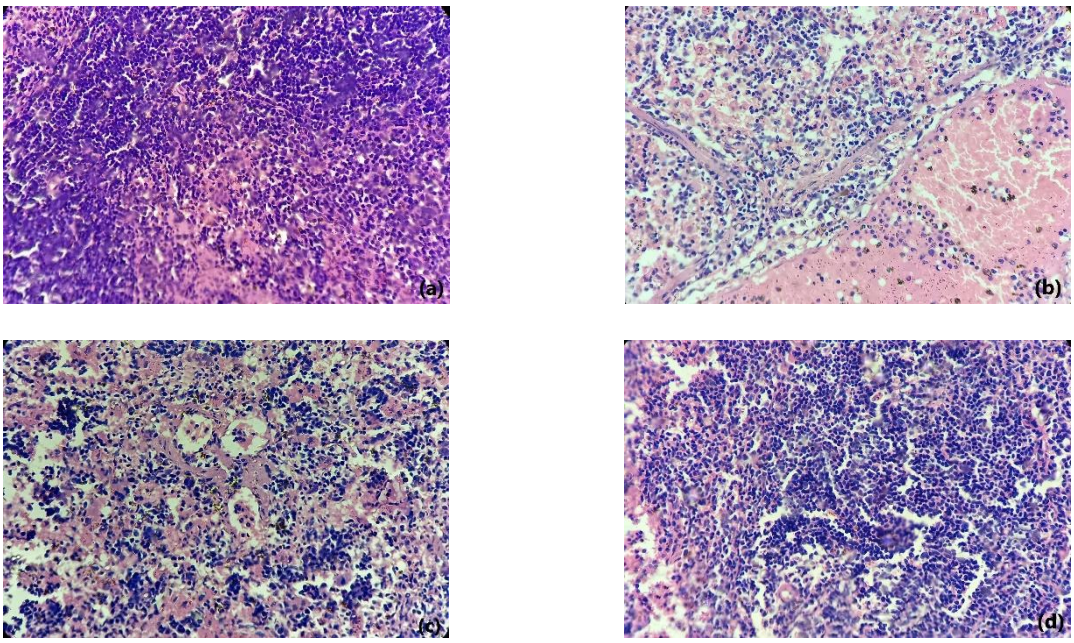

Plate : showing histology sections of spleen tissue of control rats (a) and rats administered 5000 mg/kg BW *Curcuma longa* (b), 1830 mg/kg BW *Datura metel* (c) and 3415 mg/kg BW of *Phoenix dactylifera* (d) respectively.

References

[1] S. Creton, I. C. Dewhurst, , L. K. Earl, , S. C. Gehen, , R. L. Guest, , J. A. Hotchkiss, , I. Indans, M. R. Woolhiser, R Billington. Acute toxicity testing of chemicals—opportunities to avoid redundant testing and use alternative approaches. Critical reviews in toxicology, (2010). 40(1), 50-83. https://doi.org/10.3109/10408440903401511.

[2] E. Walum Acute oral toxicity. Environmental health perspectives, (1998) 106(suppl 2), 497-503. https://doi.org/10.1289/ehp.98106497.

[3] Organisation for Economic Cooperation and Development. OECD guidelines for the testing of chemicals-425 (acute oral toxicity–up and down procedure). Organisation for Economic Cooperation and Development. (2001).

[4] E. Schlede Oral acute toxic class method: OECD Test Guideline 423. Rapporti istisan, (2002). (41), 32-36.

[5] A. Rispin, D. Farrar, E. Margosches, K. Gupta, K. Stitzel, G. Carr, M. Greene, W. Meyer, D. McCall Alternative methods for the median lethal dose (LD (50)) test: the up-and-down procedure for acute oral toxicity. ILAR journal, (2002). 43(4), 233–243. https://doi.org/10.1093/ilar.43.4.233.

[6] M. Van den Heuvel, A new approach to the classification of substances and preparations on the basis of their acute toxicity: a report by the British toxicology society* working party on toxicity. Human Toxicology, (1984). 3(2), 85-92 https://doi.org/10.1177/096032718400300202.

[7] Y Piao., Y. Liu, X. Xie Change trends of organ weight background data in Sprague Dawley rats at different ages. Journal of toxicologic pathology (2013). 26(1), 29-34. https://doi.org/10.1293/tox.26.29.

[8] W. C. Silva Faria, N. Veggi, N. H. Kawashita, F. Lemes, C. Cardoso, A. Converti, M. Moura, N. Bragagnolo Acute and subacute oral toxicity assessment of dry encapsulated and non-encapsulated green coffee fruit extracts. Journal of Food and Drug Analysis, (2020). 28(2), 337-355. https://doi.org/10.38212/2224-6614.1067.

[9] M. A. Miller, J. F. Zachary Mechanisms and morphology of cellular injury, adaptation, and death. Pathologic basis of veterinary disease, 2. (2017). https://doi.org/10.1016/B978-0-323-35775-3.00001-1.

[10] E.O.J. Ozioma, O.A.N. Chinwe Herbal medicines in African traditional medicine. Herbal medicine, (2019). 10, 191-214.

[11] A. G. Desai, G. N. Qazi, R. K. Ganju, M. El-Tamer, J. Singh, A. K. Saxena, Y. S. Bedi, S. C. Taneja, H. K. Bhat Medicinal plants and cancer chemoprevention. Current drug metabolism, (2008) 9(7), 581-591. https://doi.org/10.2174/138920008785821657.

[12] R. Rodrigo, M. Libuy, F. Feliu, D. Hasson Polyphenols in disease: from diet to supplements. Current pharmaceutical biotechnology, (2014). 15(4), 304-317. https://doi.org/10.2174/1389201015041408251138 15.

[13] A. Remesh Drug resistance in cancer chemotherapy-an overview. Int. J. Cur. Res. Rev, (2013). 5(08).

[14] S. Lev-Ari, A. Starr, A. Vexler, V. Karaush, V. Loew, J. Greif, E. Fenig, D. Aderka, R. Ben-Yosef, Inhibition of pancreatic and lung adenocarcinoma cell survival by curcumin is associated with increased apoptosis, down-regulation of COX-2 and EGFR and inhibition of Erk1/2 activity. Anticancer research, (2006). 26(6B), 4423-4430.

[15] Y. Pan, X. Wang, X. Hu Cytotoxic withanolides from the flowers of Datura metel. Journal of natural products, (2007). 70(7), 1127-1132. https://doi.org/10.1021/np070096b.

[16] Y. Xu, J. Zhang, J. Han, X. Pan, Y. Cao, H. Guo, X. Li Curcumin inhibits tumor proliferation induced by neutrophil elastase through the upregulation of α1-antitrypsin in lung cancer. Molecular oncology, (2012). 6(4), 405-417. https://doi.org/10.1016/j.molonc.2012.03.005.

[17] B. B. Nazeema, J. Julie, J. Abirami, R. Kumareasan, T. Muthukumaran, S. Rajasree, J.K. Jothi, S. Kumaran Anti-cancer activity of Datura metel on MCF-7 cell line. Asian J Pharm Clin Res, (2014). 7(5), 181-3.

[18] H. Jin, F. Qiao, Y. Wang, Y. Xu, Y. Shang Curcumin inhibits cell proliferation and induces apoptosis of human non-small cell lung cancer cells through the upregulation of miR-192-5p and suppression of PI3K/Akt signaling pathway. Oncology reports, (2015). 34(5), 2782-2789. https://doi.org/10.3892/or.2015.4258.

[19] M. Chakroun, B. Khemakhem, H. B. Mabrouk, H. El Abed, M. Makni, N. Drira, Marrakchi, N., and Mejdoub, H. (2016). Evaluation of anti-diabetic and anti-tumoral activities of bioactive compounds from Phoenix dactylifera L's leaf: In vitro and in vivo approach. Biomedicine & Pharmacotherapy, 84, 415-422. https://doi.org/10.1016/j.biopha.2016.09.062.

[20] F. Khan, F. Ahmed, P. N. Pushparaj, A. Abuzenadah, T. Kumosani, E. Barbour, M. AlQahtani, K. Gauthaman. Ajwa date (Phoenix dactylifera L.) extract inhibits human breast adenocarcinoma (MCF7) cells in vitro by inducing apoptosis and cell cycle arrest. PloS one, (2016). 11(7), e0158963. https://doi.org/10.1371/journal.pone.0158963.

[21] Council for International Organizations of Medical Sciences. (1985). International guiding principles for biomedical research involving animals. Altern Lab Anim., 12, ii.
[22] N. Toudert, A. Zaiter, S. E. Djilani, N Dada., A. Djilani, A. Dicko Impact of methanol–water ratio of leaf and root extracts of ampelodesma mauritanicaon the antioxidant activity, and effect of different solvent extraction on phenolic compounds quantification. Acta Sci. Nutr. Health, (2017). 1, 3-7.
[23] K. Uthayarasa, , K. Pathmanathan, J. P. Jeyadevan, E. C. Jeeyaseelan. Antibacterial activity and qualitative phytochemical analysis of medicinal plant extracts obtained by sequential extraction method. IJIB, (2010) 10(2), 76-81.
[24] A. Pandey, S Tripathi. Concept of standardization, extraction and pre phytochemical screening strategies for herbal drug. Journal of Pharmacognosy and Phytochemistry, (2014). 2(5), 115-119.
[25] E. Chinedu, D. Arome, F. S. Ameh A new method for determining acute toxicity in animal models. Toxicology international, (2013). 20(3), 224. https://doi.org/10.4103/0971-6580.121674.
[26] S. A. Saganuwan Toxicity studies of drugs and chemicals in animals: an overview. Bulgarian Journal of Veterinary Medicine, (2017). 20(4). https://doi.org/10.15547/bjvm.983.
[27] R. D. Bruce. An up-and-down procedure for acute toxicity testing. Fundamental and Applied Toxicology, (1985). 5(1), 151-157. https://doi.org/10.1016/0272-0590(85)90059-4.
[28] W. Underwood, R. Anthony. AVMA guidelines for the euthanasia of animals: 2020 edition. Retrieved on March, (2020). 2013(30), 2020-1.
[29] S. A. Saganuwan. Arithmetic-Geometric-Harmonic (AGH) method of rough estimation of median lethal dose (LD50) using up-and-down procedure. J Drug Metab Toxicol, (2015). 6(2), 1-3. https://doi.org/10.1016/j.toxlet.2014.06.454.
[30] R. A. Drury, R. Cancerson Carlton's Histo-pathological Techniques. 4th ed. Oxford University press. pp(1976). 21- 70
[31] M. A. Giordani, T. C. M. Collicchio, S. D. Ascêncio, D. T. de Oliveira Martins, S. O. Balogun, I. G. C. Bieski, N. H. Kawashita Hydroethanolic extract of the inner stem bark of Cedrela odorata has low toxicity and reduces hyperglycemia induced by an overload of sucrose and glucose. Journal of Ethnopharmacology, (2015). 162, 352-361. https://doi.org/10.1016/j.jep.2014.12.059.
[32] P. V. Turner, T. Brabb, C. Pekow, M. A. Vasbinder. Administration of substances to laboratory animals: routes of administration and factors to consider. Journal of the American Association for Laboratory Animal Science, (2011). 50(5), 600-613.
[33] E. A. Thackaberry. Vehicle selection for nonclinical oral safety studies. Expert Opinion on Drug Metabolism & Toxicology, (2013). 9(12), 1635-1646. https://doi.org/10.1517/17425255.2013.840291.
[34] E. O. Erhirhie, C. P. Ihekwereme, E. E. Ilodigwe. Advances in acute toxicity testing: strengths, weaknesses and regulatory acceptance. Interdisciplinary toxicology, (2018). 11(1), 5-12. https://doi.org/10.2478/intox-2018-0001.
[35] D. G. Maheshwari, N. K. Shaikh An overview on toxicity testing method. Int J Pharm Technol, (2016). 8(2), 3834-3849.
[36] A. Hodge, B. Sterner Toxicity classes in: Canadian Centre for occupational health and Safety. Copyright@ 1997–2010.
[37] D. L. Eaton, S. G. Gilbert Principles of toxicology. Casarett & Doull's Toxicology. The Basic Science of Poisons. CD Klaassen (ed), (2008). 11-34.
[38] D. Curtis Casarett and Doull's TOXICOLOGY The Basic Science of Poisons Eighth Edition. (2013).
[39] E. M. Faustman, S. M. Bartell. Review of noncancer risk assessment: Applications of benchmark dose methods. Human and Ecological Risk Assessment: An International Journal, (1997). 3(5), 893-920. https://doi.org/10.1080/10807039709383733.