International Journal of Pharmacology and Toxicology, 10 (1) (2022) 1-9

International Journal of Pharmacology and Toxicology

Website: www.sciencepubco.com/index.php/IJPT

Research paper

Evaluating the protective impact of pumpkin seeds oil against ciprofloxacin induced hepatorenal toxicity in the male albino rats

Hanan Sabry Abd El-Shafi Ahmed [1] *, Ashraf A. A.Elkomy [2], Enas A.H. Farag [3]

[1] *Pharmacist at Department of Pharmacology, Faculty of Pharmacy, October Six University, Six October city, Giza, Egypt*
[2] *Department of Pharmacology, Faculty of Veterinary Medicine, Benha University, 13736 Moshtohor, Qaliobiya, Egypt*
[3] *Deputy of Animal Health Researchers Institute for Regional Laboratories.AHRI.ARC*
**Corresponding author E-mail: Hanan.sabriiiii@gmail.com*

Abstract

Background: Ciprofloxacin increased the production of reactive oxygen species, As a result of its intracellular accumulation, which leads to extracellular membrane damage, resulting in the release of apoptotic components into the bloodstream, a condition known as apoptosis.
Objective: The goal of this study is to investigate the protective effect of pumpkin seeds oil (PSO), a well-known natural antioxidant against Ciprofloxacin-induced liver and kidney impairment (CPFX[i]).
Material and methods: Forty-Four male albino rats weighing approximately 180–200 gm were formed. (n = 10): (1) control saline, (2) PSO [ii] (4ml/kg/day orally for 4 weeks), (3) CPFX (80mg/kg/day orally for 2 weeks), and (4) PSO (4ml/kg/day orally for 4 weeks) + CPFX (80mg/kg/day orally for 2 weeks), starting on the first day of the third week. Finally, Serum and tissue specimens are collected at the conclusion of the experiment for biochemical and histopathological examination. Results: It ended up being found in the CPFX-treated group. ALT [iii], AST [iv], and TNFα[v] levels were all significantly elevated in the serum. While this medication reduced the hepatocellular content of GSH [vi], it increased the tissue content of MDA [vii], which clearly shows oxidative stress Reduced BCL2[viii] levels also indicate the presence of apoptosis. CPFX causes an increase in kidney-specific markers such as creatinine and urea, indicating kidney disease. When PSO was combined with CPFX BAX [ix], MDA, AST, ALT, and TNFα levels were considerably reduced, while GSH and BCL2 levels increased, indicating that PSO has antioxidant action and reduces apoptosis. Additionally, the renal function parameters improved, as seen by lower serum creatinine and urea levels.
Conclusion: In rats, employing PSO as a concurrent prophylactic therapy while administering CPFX effectively reduced CPFX-induced oxidative stress and apoptotic damage. PSO could be used as a preventive medication to prevent CPFX-induced cellular damage to the kidneys and liver.

Keywords: *Pumpkin Seed Oil; Ciprofloxacin; Antioxidant; Apoptosis; Tumor Necrosis Factor; GSH.*

1. Introduction

Ciprofloxacin (CPFX) is a 2nd generation quinolone antibiotic that has intracellular penetration and is effective against aerobic gram positive and atypical bacteria. It is one of the most commonly used bactericidal antibiotics because of its effectiveness against many systemic infections and serious bacterial infections, particularly hospital acquired infections of the urinary tract, lower respiratory tract, and skin. CPFX has a high bioavailability, good to high tissue penetration, and is relatively safe when taken orally. According to clinical data, CPFX treatment at recommended doses led to a rise in liver injury indicators. ALT, GGT[i], AST, ALP[ii], and total bilirubin are examples of these enzymes. (Papich, 1998) (Cherubin et al., 1992) (Hemieda et al., 2019; Pham et al., 2019; Wright et al., 2018).
CPFX therapy causes hepatotoxicity in a dose-dependent manner. CPFX causes oxidative stress and apoptosis at many levels, including serum and organs. Superoxide anions production has risen. and oxidative stress biomarkers MDA, PC[iii], H2O2[iv], and NO [v]and/or decrease in hepatic level antioxidant enzymes GSH, SOD[vi], CAT[vii], GPX[viii], and GST [ix], are all enzymes that help to detoxify the body .CPFX activates tumour necrosis factor receptors (TNF receptors), also known as death receptors, which leads to an increase in the synthesis of TNF α and pro-apoptotic factor BAX, while lowering anti-apoptotic BCL 2(AL-Rikaby et al., 2016; Elbe et al., 2016) (Farombi, 2013) (Gomes et al., 2017) (Aranha et al., 2002) (Lim et al., 2018).
The incidence of raised serum creatinine and urea levels associated with ciprofloxacin medication has been reported to range from 0.2 to 1.3 percent in human patients, according to published data. Furthermore, azotaemia rates with ciprofloxacin have been reported to range between 1.8 and 13.1 per 1000 individuals treated with the drug. The absence of any distinguishing clinical symptoms of nephrotoxicity other than an ascend in urea and creatinine serum concentrations after administration of a fluoroquinolone, on the other hand, warrants maintaining a high index of suspicion. Almost all incidences of acute renal failure caused by CPFX medication have been linked to patients over the age of 50.(Lipsky &Baker, 1999) (Anand, 1993; Lo et al., 1993).

Copyright © Hanan Sabry Abd El-Shafi Ahmed et al. This is an open access article distributed under the Creative Commons Attribution License, which permits unrestricted use, distribution, and reproduction in any medium, provided the original work is properly cited.

Recently, scientists have become interested in the significance of medicinal plants, natural food intake, and their role in the control and management of certain disorders. (Balick et al., 2000). Many natural compounds have antioxidant properties because they function as scavengers for free radicals. In comparison to synthetic antioxidants like butylated hydroxyl toluene and butylated hydroxylanisol, natural source medicines have fewer toxicity and adverse effects. (Retnam &Martin, 2006).
Minerals are essential in the human body's daily supplements since they play such an important role in all of the body's processes. The pumpkin is a member of the family (cucurbitaceae). Pumpkins (cucurbita pepo l.) are a natural source of proteins, fibres, tocopheroles, phytosterols, and a few key minerals like zinc, selenium, magnesium, potassium, and phosphorus. (Eraslan et al., 2013). Because of its antioxidant properties, pumpkin seeds could be used as a functional food or medicine. Its secondary metabolites, such as Essential fatty acids-omega three, six, nine and unsaturated fatty acids, phytosterols, caratonoids, vitamin E, and A, which are found in high concentration in plant consumption, will play a major role in disease prevention. (Murkovic et al., 1996).
PS^{x}'s zinc concentration acts as a direct and indirect antioxidant, neutralising free radical generation by managing the iron or copper binding sites of lipids, proteins, and DNA molecules.(Amin &Thakur, 2013). PSO's antioxidant properties have shown to be effective in lowering blood pressure, improving fertility, and lowering the risk of arteriosclerosis, as well as playing a key role in fat metabolism in organs such as the liver.(Gajewski et al., 2008). Pumpkin seed oil's antioxidant activity and ability to scavenge free radicals may be the primary mechanisms underlying its beneficial effects. (K Ramadan et al., 2016)
The Aim of this Thesis: To assess the potential anti activity of pumpkin seed oil on rat hepatic-renal toxicity caused by ciprofloxacin.

2. Materials and methods

2.1. Agents utilized in this research

- Ciprofloxacin without excipient (ciprofloxacin- hydrochloride) (scientific research department, Egyptian International Pharmaceutical Industries Company - EIPICO CAIRO, EGYPT).
- Oil from pumpkin seeds, healthy fruits of (fluted pumpkin) were obtained from a local market at October city, Giza. The plant samples were identified and verified by a team of experts (pharma-cog-nosy department, faculty of pharmacy, 6 October University).

2.2. Oil preparation (cold extraction method)

The cleaning and pressing of oil seeds are the two most important stages in the processing of plant oil. Unnecessary extra contaminants were removed from the seeds, including debris, plant fragments, and damaged seeds. This provides a constant flow of oil. A special machine or a heat exchanger uses the heat from the warm press cake to pre-warm the seed to around 25 °C. Warming the seed to average temps above 25 °C adds nothing new. The pumpkin oil was squeezed using screw presses of the CA 59 G type (IBG Monforts Oekotec GmbH).The screw rotated at a rate of 20 revolutions per minute (rpm). (Rabrenović et al., 2014).

2.3. Experimental design

Forty male albino rats, weighing between 180 and 200 grams. That was obtained from the Cairo, Egypt-based animal house of biological products and vaccinations (VASERA). They were kept in separate metal cages (10 rats per cage) at a temperature of 35°C ± 3°C and were subjected to a dark/light cycle. They were fed bread and green leafy vegetables, and they had unfettered access to clean water. They were given a week to acclimate before beginning the trial. At Benha University's Faculty of Veterinary Medicine's Laboratory Animal Research Centre.
Group (1): control normal group (received 4ml/kg /day saline only by oral for 4 weeks.
Group (2): was given 4ml/kg /day pumpkin seeds oil only by oral for 4 weeks (Eraslan et al., 2013) with a few tweaks for a more hepatic-renal impact
Group (3) : was given(4ml/kg /day saline only by oral for 2 weeks) then start receiving hydrochloride Ciprofloxacin (80 mg dissolved into 10 ml saline /kg /day for 2 weeks) This dose was chosen based on the manufacturer's advice for community-acquired pneumonia recommendations. (Rizzato &Allegra, 1997).
Group (4): was given 4ml/kg /day pumpkin seeds oil only by oral for 4 weeks) then start Administration Ciprofloxacin hydrochloride at the first day of third week (80 mg dissolved into 10 ml saline /kg /day for 2 weeks).
*The handling of animals was precisely adhered to the protocol of Guide for the Care and Use of Laboratory Animals (NIH publication, 1996 (Council, 2010)). The protocol was approved by the Research Ethical Committee of the Faculty of veterinary medicine, Benha University, Egypt.

2.4. Sampling

At the end of experiment showed no death in experimental rats.

2.4.1. Blood samples

In all groups, samples were collected 24 hours following the last dose. Each rat in the group had blood drawn from the median canthus of the eye for biochemical analysis. The blood sample was drawn without the use of anticoagulants in order to Clear serum should have been kept separate for bioassay. Serum AST and ALT levels were assessed in these serum samples, Tumor necrosis factor TNF α, serum urea, and serum creatinine.

2.4.2. Liver and kidney specimen

After sacrificing, the liver and kidneys are prepared soon after blood sampling. The initial section of the liver was employed in biochemical analysis in order to estimate the concentration. BCL2, pro-apoptotic BAX levels as apoptotic markers, and MDA, GSH as oxidative stress signals The second section of the liver and kidneys were then taken for histological analysis..

2.5. Biochemical parameters measurement

ALT kits purchased from (BiOMED DIAGNOSTIC, Cambridge, united kingdom) AST kits purchased from (Jiancheng Co., Nanjing, China) according to the procedures outlined in(Reitman &Frankel, 1957). BAX, BCL2 and Inflammatory mediators TNFα by Enzyme-linked immunosorbent assay (ELISA) kits for concentration did buy from (CUSABIO, HOUSTON, USA) working according to(Yeh et al., 2002). Determination of creatinine and urea used kits purchased from (MEDIBENA, AUSTRIAl, EUROPE) according to the method of(Davalos-Misslitz et al., 2007) , (Levinson, 1978) respectively. Determination of GSH, and MDA by kits purchased from (BIODIAGNOSTIC, Cairo, Egypt) in line with the recommendations mentioned in (Beutler &Kelly, 1963),(Ohkawa et al., 1979) Respectively.
The additional compounds in this investigation were bought from SIGMA, United States.

2.6. Histopathological study

Autopsy specimens were taken from the kidney and liver of assorted groups of rats and fixed in 10% formalin: saline for seven days.. The samples were then dehydrated in a succession of alcohols, cleaned in toluene, and embedded in paraplast (Sherweed Medical Co, USA). Blocks were cut at a length of 5-7 m. Dewaxed sections were rehydrated in a series of alcohols before staining with Harris hematoxylin (Cole Parmer, USA) and counterstaining with 1% aqueous eosin (Sigma, USA). The sections were mounted in DePeX (GURR, BDH, UK) and reviewed under a light microscope.. Under an Olympus Vanox photomicroscope (Olympus, USA), representative slides were captured (Al-Naqeeb et al., 2003).

2.7. Statistical analysis

Data was analyzed using IBM SPSS advanced statistics (Statistical Package for Social Sciences), version 24 (SPSS Inc., Chicago, IL). Numerical measurements were described as mean (standard deviation) and median (range). The variables were tested for normality using Kolmogrov-Smirnov test and Shapiro-Wilk test. The variables were not normally distributed, comparisons between the 4 groups were performed using the Kruskal-Wallis test that followed by post hoc using Mann Whitney U test. The p-values were adjusted for inflation by the Bonferroni corrections.
A p-value less than or equal to 0.05 was considered statistically significant. All tests were two tailed.

3. Results

PSO (pumpkin seeds oil) was a dark green liquid with a viscous texture. CPFX (Ciprofloxacin) caused a significant (P 0.05) increase in serum levels of AST, ALT, creatinine, and urea when compared to a control group and a PSO treated group as a stander. PSO in pairing with CPFX restricts CPFX's toxicity. Table. 1, and fig.1.

Table 1: Effect of PSO On CPFX-Induced Changes in Serum Levels of the Liver and Kidney Status Markers in the Serum of Male Albino Rats

	CON	PSO	CPFX	PSO+CPFX
AST	19.04±2.10 (b)	20.25±1.49 (b)	82.80±1.16 (a)	35.60±3.71 (ab)
ALT	26±2.09 (b)	24.75±1.89 (b)	68.20±4.47(a)	43.20±5.05 (ab)
Creatinine	0.25±0.05 (b)	0.21±0.03 (b)	1.87±0.15 (a)	0.50±0.08 (ab)
Urea	38±4.36 (b)	33.50±3.28 (b)	104±6.61(a)	63.20±5.42 (ab)

- Con=control, PSO= pumpkin seeds oil, CPFX=ciprofloxacin, AST (aspartate aminotransferase) and ALT (alanine aminotransferase).
- Values were expressed as mean and standard division
- Cells sharing same letters were not statistically significant at p≤ 0.05. All tests were 2 tailed.

CPFX treated Rats shows high hepatic contents of oxidative stress indicators such MDA increased significantly in a dose-dependent way as compared to the control group and reveals a significant drop in liver antioxidants such as reduced glutathione (GSH). In particular, when compared to groups treated primarily with CPFX, co-administration of PSO as a prophylactic drug diminished the elevated hepatic content of peroxidation markers while enhancing the lower levels. Table (2), Figure (2).

Table 2: The Impact of PSO On CPFX-Induced Oxidative Stress in Male Albino Rat Hepatocytes

	CON	PSO	CPFX	PSO+CPFX
MDA	48.44±4.95(b)	45.70±1.16 (b)	165.82±6.12 (a)	66.36±5.40 (ab)
GSH	87.24±5.11(b)	97.98±2.90 (b)	33.04±4.51(a)	78.24±4.17 (ab)

- Con=control, PSO= pumpkin seeds oil, CPFX=ciprofloxacin, MDA= Malondialdhyde, and GSH= Reduced Glutathione.
- Values were expressed as mean and standard division
- Cells sharing same letters were not statistically significant at p≤ 0.05. All tests were 2 tailed

The dosing of CPFX to rats resulted in dose-dependent variations in apoptotic markers in the liver, as shown in table (3) and Fig. 3 This caused an increase in TNFα and BAX levels, as well as a significant decrease in BCL2 levels. In compared to the CPFX alone treated group, co-administration of PSO with CPFX shuts down the CPFX-induced apoptotic by boosting anti-apoptotic factor BCL2 and diminishing proapoptotic factor BAX. PSO administration of rats had no adverse effects on any of the biochemical markers studied.

Table 3: PSO's Effect on CPFX-Induced Apoptotic Cell Death in Male Albino Rats Serum and Liver Tissues

	CON	PSO	CPFX	PSO+CPFX
BAX	77.58±5.26 (b)	71.70±10.41 (b)	222.90±7.33 (a)	103.583.84 (ab)
BCL2	173.58±4.33 (b)	178.58±5.91 (b)	73.32±7.51 (a)	149.10±2.15 (ab)
TNF α	31.96±2.14 (b)	31.18±2.05 (b)	131.16±8.60 (a)	63.62±5.43 (ab)

- Con=control, PSO= pumpkin seeds oil, CPFX=ciprofloxacin, BCL2= B cell lymphoma protein 2, BAX= BCL2 associate X proteins and TNFα= tumor necrosis factor α
- Values were expressed as mean and standard division

- Cells sharing same letters were not statistically significant at p≤ 0.05. All tests were 2 tailed.

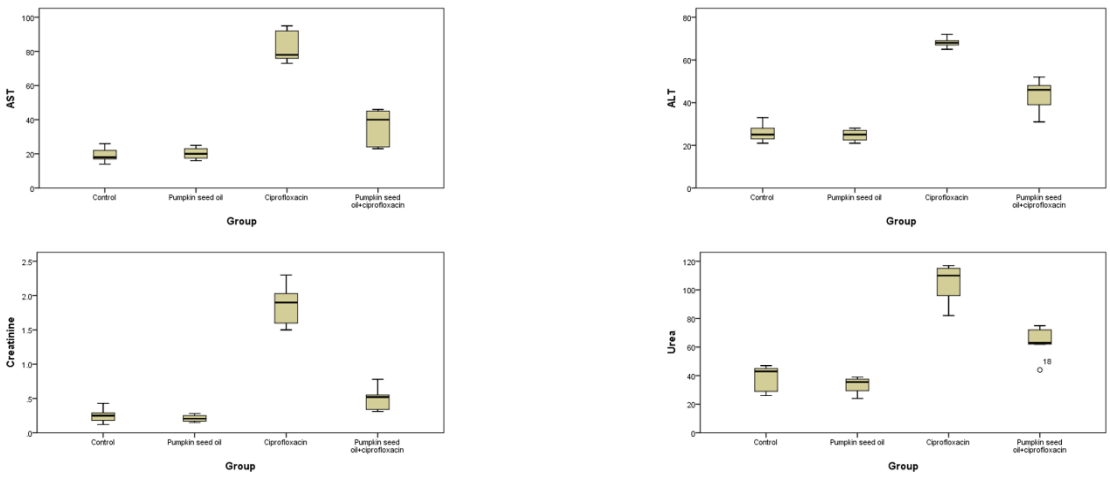

Fig. 1: Box Plot Showing Distribution of AST, ALT, Creatinine, and Urea Levels in the Assorted Rat Groups.

Fig. 2: MDA and GSH Levels in the Assorted Rat Groups Analysed. the Mean± Standard Error of the Mean Is Used to Represent the Values. $P^A \leq 0.05$ Versus Saline Control Group, $P^B \leq 0.05$ Versus CPFX Treated Rats, and $P^c \leq 0.05$ Versus PSO Treated Rats.

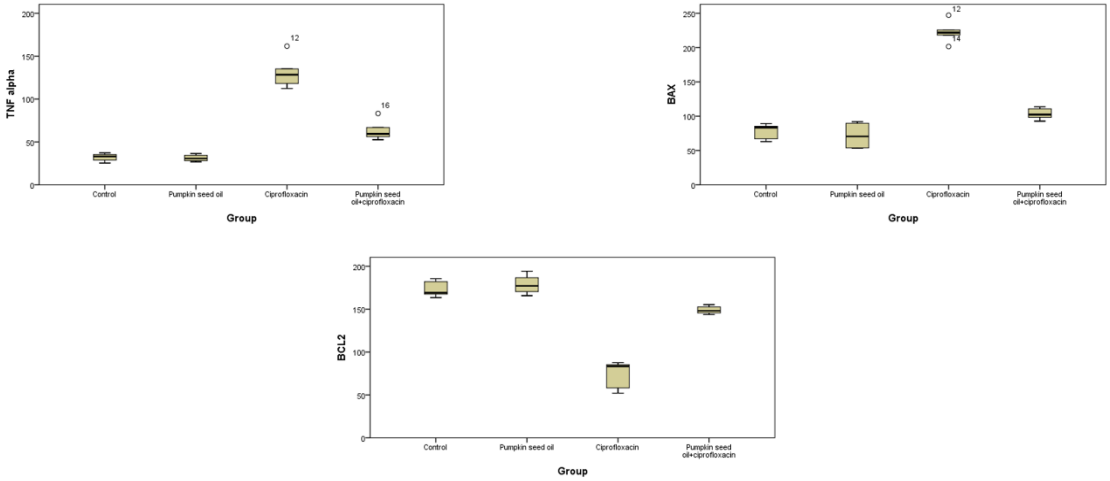

Fig. 3: BAX, BCL 2, and Tnfα Factors Levels in the Various Rat Groups Analysed. the Mean± Standard Error of the Mean Is Used to Represent the Values. $P^A \leq 0.05$ Versus Saline Control Group, $P^B \leq 0.05$ Versus CPFX Treated Rats, and $P^c \leq 0.05$ Versus PSO Treated Rats.

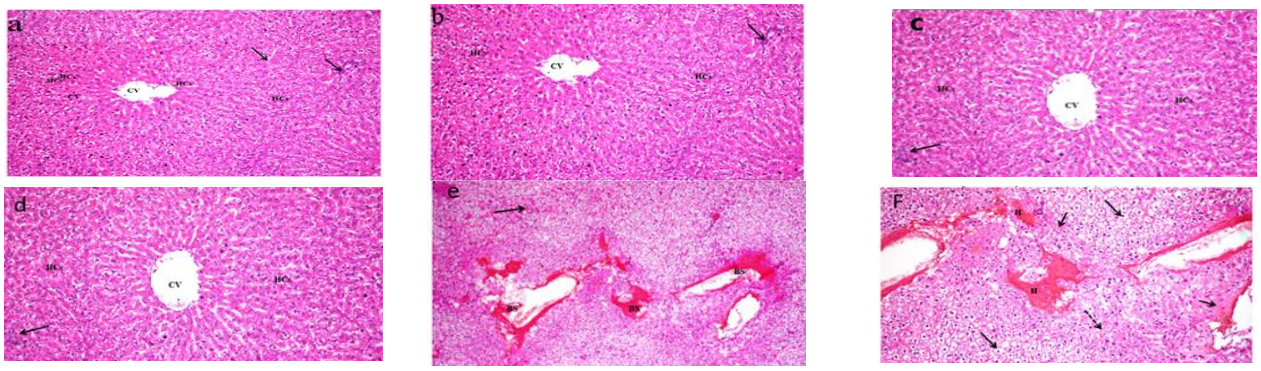

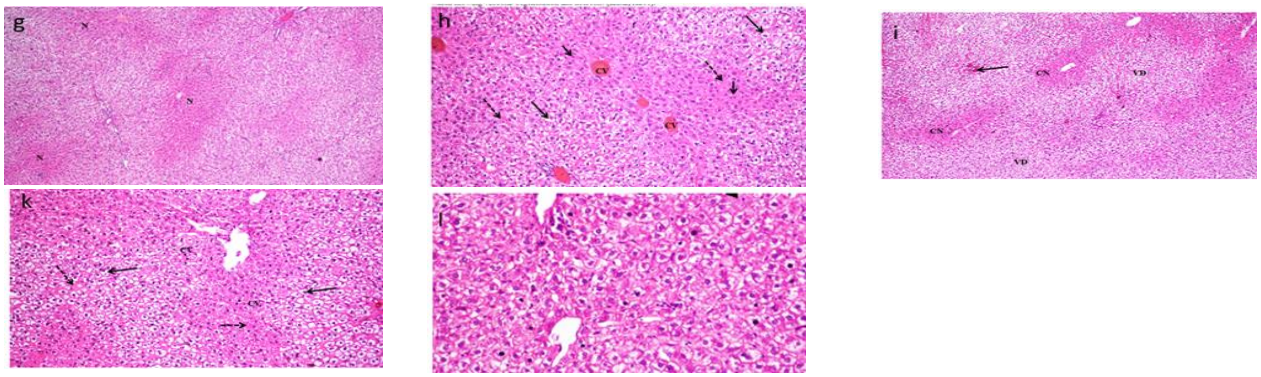

Fig. 4: A) Liver Histopathology of Control Saline Treated Rats Group (1) Demonstrating the Central Vein's Normal Histological Structure (CV), Portal Areas (Arrow) And Hepatic Cells (Hcs). (H&E, X100). (B) Liver Histopathology of Control Saline Treated Rats Group (1) Histological Structure of The Central Vein (CV), Portal Areas (Arrow) And Hepatic Cells (Hcs). (H&E, X200. (C) Liver Histopathology of Normal Rats Treated with Pumpkin (Group 2) Showing Normal Central Vein (CV), Portal Area (Arrow) And Hepatic Parenchymal Cells (Hcs). (H&E, X100). (D) Liver Histopathology of Normal Rats Treated with Pumpkin (Group 2) Showing Normal Central Vein (CV), Portal Area (Arrow) And Hepatic Parenchymal Cells (Hcs). (H&E, X200). (E) Liver Histopathology of Oral CPFX (Group 3) Showing Large Blood-Filled Spaces (BS) Replacing the Hepatic Parenchyma with Severe Dilatation and Congestion of the Hepatic Sinusoids (Arrow). (H&E, X200). (F) Liver Histopathology of Oral CPFX (Group 3) Showing Severe Vascular Degeneration (Arrow) And Necrosis of The Hepatic Cells (Dashed Arrow) with Extensive Area of Haemorrhage (H) Replacing the Hepatic Parenchyma and Surrounded by Necrotic Hepatic Cells (Short Arrow). (H&E, X400). (G) Liver Histopathology of Oral CPFX (Group 3) Showing Focal Areas of Necrosis of The Centrilobules (CN), The Hepatic Cells Around Which Showing Vascular Degeneration and Necrosis. (H&E, X100). (H) Liver Histopathology of Oral CPFX (Group 3) Showing Hepatocellular Vascular Degeneration (Narrow), Necrosis (Dashed Arrow), Nuclear Pyknosis (Short Arrow), And Centrilobular Coagulative Necrosis Around the Congested Central Vein (CV). (H&E, X200). (I)Liver Histopathology of CPFX Treated Rats Protected with PSO (Group4) Showing Moderate Degree of Centrilobular Necrosis (CN) Of the Hepatic Cells with Vascular Degeneration (VD) Of the Peripheral Cells. Notice Mild Congestion of Few Central Veins (Arrow). (H&E, X100). (K) Liver Histopathology of CPFX Treated Rats Protected with PSO (Group4) Showing Vacuolar Degeneration (Arrow) Of the Hepatic Cells at The Periphery of the Hepatic Lobule with Scattered Necrotic Cells (Dashed Arrow) Particularly at the Per Acinar Areas. (H&E, X200). (L) Liver Histopathology of CPFX Treated Rats Protected with PSO (Group4) Showing Moderate Hepatocellular Vacuolation (Arrow) With Scattered Necrotic (Dashed Arrow) Cells. (H&E, X200).

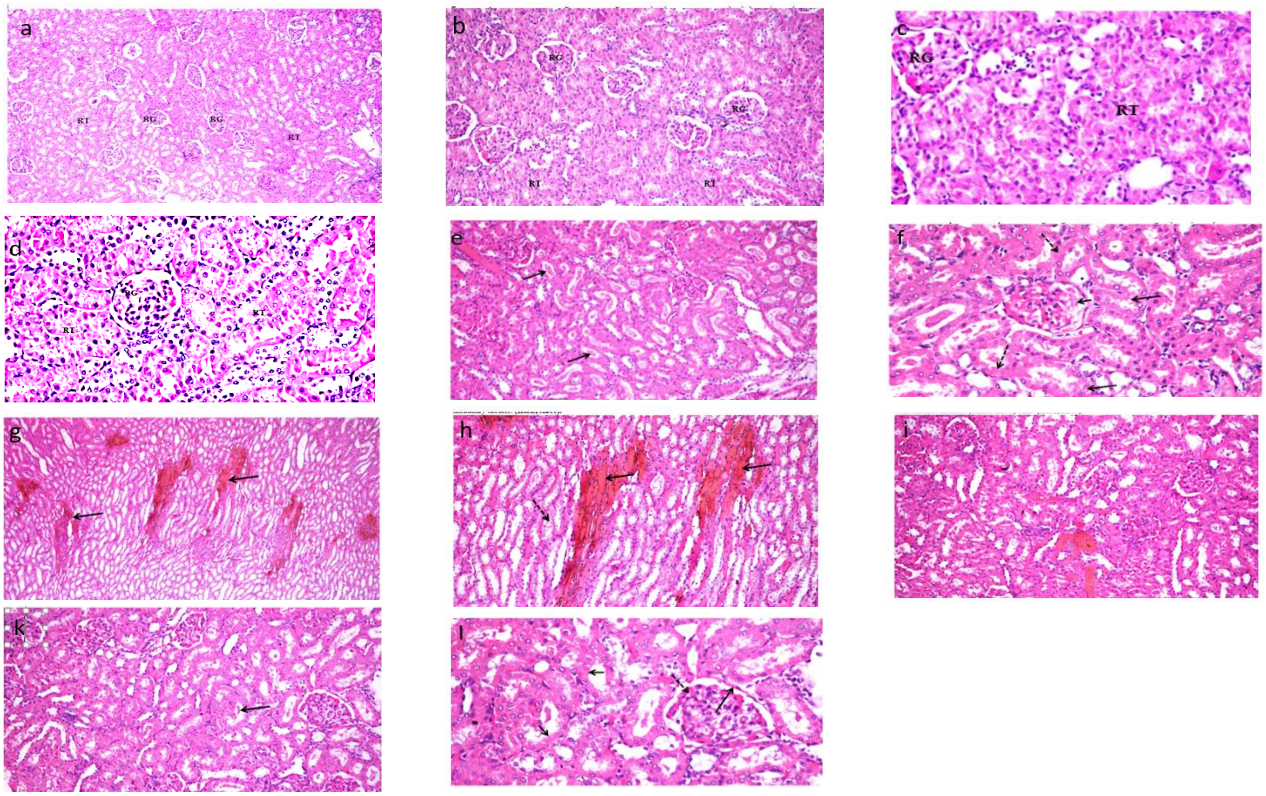

Fig. 5: A) Kidney Histopathology of Normal Control Rats Treated with Saline Group (1) Showing Normal Renal Glomeruli (RG) And Tubules of the Kidney. (H&E, X100). (B) Kidney Histopathology of Normal Control Rats Treated with Saline Group (1) Displaying the Normal Histological Structure of The Renal Glo-Meruli (RG) And Tubules of the Kidney). (H&E, X200). (C)Kidney Histopathology of PSO Treated Rats (Group 2) Demonstrating Normal Histological Structure of Renal Glomeruli (RG) And Tubule (H&E, X200). (D) Kidney Histopathology of PSO Treated Rats (Group 2) Depicting the Renal Glomeruli's Normal Histolog-Ical Structure, And Renal Tubules (RT). (H&E, X400). (E) Kidney Histopathology of Oral CPFX (Group 3) Showing Marked Eosinophilic Renal Cast (Arrow) in the Lumen of the Renal Tubules and Widespread Tubular Epithelial Linings' Degenerative and Necrotic Changes. (H&E, X200). (F) Kidney Histopathology of Oral CPFX Treated Rats (Group 3) Depicting Swelling with Vascular Degeneration (Arrow) and Necrosis (Faded Arrow) of the Renal Tubular Epithelium, As Well As the Presence of Dispersed Eosinophilic Cast (Narrow Arrow) in the Bowman's Space and Thickening of the Bowman's' Sac. (H&E, X400). (G) Kidney Histopathol-Ogy of Oral CPFX (Group 3) Showing Marked Haemorrhagic Renal Cast (Arrow) Within in the Lumen of Medullary Tubules. (H&E, X200). (H) Kidney Histo-Pathology of Oral CPFX (Group 3) Showing Haemorrhagic Renal Cast (Arrow) in the Lumen of the Medullary Tubules with Degenerated and Desquamated (Dashed Arrow) of the Some Medullary Tubular Epithelium. (H&E, X400). (I) Kidney Histopathology of CPFX Treated Rats Protected with PSO (Group4) 1showing Mild to Moderate Stage of Tubular Epithelia Degenerative and Dead Cells. (H&E, X200). (K) Kidney Histopathology of CPFX Treated Rats Protected with PSO (Group4) Demonstrating Mild Necrobiosis Improvements in the Renal Tubular Epithelial Linings with Scattered Eosinophilic Granular Cast (Arrow) in the Lumen of Some Tubules (H&E, X200). (L) the Kidney

Histopathology Of CPFX-Treated Rats Protected with PSO (Group 4) Clearly Demonstrates Minor Thickness of the Parietal Surface (Curve) of the Bowman's Sac. As Well As The Glomerular Capillary (Dashed Arrow) with Mild Degeneration, Necrosis (Short Arrow), And Very Few Desquamated Renal Tubular Epithelial Cells. (H&E, X400).

4. Discussion

Because CPFX is predominantly metabolised in the 2, it can cause liver impairment in humans and animals. In terms of serum biochemical findings, a recent study revealed that administering CPFX to male albino rats causes dose-dependent hepatocellular injury as proven by significant elevations of ALT and AST. Many clinical reports have shown that treatment with CPFX at therapeutic doses causes elevations in liver injury identifiers such as alanine transaminase ALT, and AST, and our findings are consistent with these findings. (Adikwu &Brambaifa, 2012; Pham et al., 2019). The increased serum levels of ALT and AST indicate cellular leakage, permeability disequilibrium in cell membranes, and a deterioration in mitochondrial hepatocellular (Hwang et al., 2007).

Although the mechanism of CPFX-induced hepatocellular damage is unknown, researchers are increasingly interested in the possibility of superoxide anions (metabolic by products) and anti - oxidants in health and disease.. (Battino et al., 1999). The formation of free radicals by CPFX may activate the lipid peroxidation and oxidative stress pathways, leading to alterations in cellular membrane and intracellular enzyme leakage into the bloodstream (Adikwu &Brambaifa, 2012).

Our findings back up this explanation, as CPFX causes hepatocellular injury by increasing oxidative stress. The collected results showed a significant elevation in MDA content in the liver tissue of CPFX-treated rats. CPFX treated rats with just a 100 mg per 1 KG monotherapy induce liver peroxidation at the liver tissue, according to previous studies recorded by (Weyers et al., 2002). CPFX also causes an increase in MDA concentration in liver tissue, which indicates lipid peroxidation. (Taslidere et al., 2016). According to one recent report, addressed the idea of oxidative stress and tissue damage as a possible mechanism of CPFX hepatocellular injury. CPFX therapy in rats was reported to cause MDA levels to have risen, confirming lipid peroxidation. in liver tissue, according to published research(Afolabi &Oyewo, 2014). ROS are generated as a By Product of mitochondrial function and play a vital role in signal transduction pathways. Conversely, peroxidation, refers to elevated quantities of ROS in the cells, which have been associated with the onset of cardiac diseases, neurodegenerative, malignancy, and other conditions (Snezhkina et al., 2019). Antioxidant defence systems, such as glutathione reductases, are initiated by viable cells to protect them from the detrimental consequences of superoxide anion (Patlevič et al., 2016). Plant and animal cells, as well as microbes, were shown to have cytoplasmic, mitochondrial, and nuclear GR[xi] content. (Kehrer et al., 2010). GSH reductase is a flavoprotein that converts glutathione from its oxidised form GSSG to its reduced form GSH using NADPH as a reducing cofactor(Prast-Nielsen et al., 2011). As a result, the maintenance of GSH content across cellular is the responsibility of these enzymes. As a response, it is critical in maintaining the cell by detoxifying xenobiotics such as medicines, poisonous and cancerous compounds(Hasanuzzaman et al., 2019; Main et al., 2012). While the enzyme GR is suppressed, leading to a drop in GSH concentration. in the presence of high xenobiotic concentrations inside the tissues, resulting in catastrophic pathologies(Ballatori et al., 2009). In this context, record significant decrease in GSH level in liver tissue of CPFX treated rats parallel to increase in lipid peroxidation marker MDA and histopathological alterations reflects that CPFX treatment toxicity mechanism induced by oxidative stress and cell damage.

Apoptosis is a phrase that refers to a programmed cell death that can occur in either a healthy or unhealthy physiological state. The intrinsic pathway, which acts in mitochondria, or the intrinsic pathway, which is activated by abnormalities in cell membrane receptors, are the two pathways by which the apoptotic process is triggered and induce different disease(Kroemer et al., 2007). Increases in pro-apoptotic proteins such as p53, BAX, and BAK induced intrinsic pathway apoptosis, which was paralleled by a decrease in anti-apoptotic BCL2 and BCL-xl. This pathway provokes mitochondrial degeneration and cell membrane permeability to be disrupted, allowing mitochondrial apoptotic proteins to leak into the blood system, activating the caspase family 3 and 9 and triggering the extrinsic pathway of apoptosis. Cell death receptors can be found on the cell membranes of several organs. TNF receptors, TNF-inducing ligand-related apoptosis receptors, and FAS receptors are just a few of the minor cells death receptors that have been discovered so far. are all triggered by caspase 8, which promotes caspase 3,9,7, which triggers cell death receptors and induces apoptosis. The results of this analysis show that CPFX induces apoptosis in cells. The CPFX-treated rats had a dose-dependent substantial rise in the apoptotic markers proapototic factor BAX and TNFα in their liver tissue. CPFX-treated rats' liver tissue had a substantial drop in the anti-apoptotic factor BCL2. Previous research on CPFX-treated humans demonstrated a rise in apoptotic markers, indicating apoptotic activity (Aranha et al., 2000). CPFX induction in male rats resulted in an increase in apoptotic bodies in liver tissue after long-period use, as well as changes in histological specimens. (Taslidere et al., 2016). The germ cells of seminiferous tubules in CPFX-treated rats showed abnormalities. (Khaki et al., 2008).

CPFX induction in rats for a long time, on the other hand, causes apoptosis due to its ability to increase oxidative stress and tissue damage. Even though ciprofloxacin is primarily excreted by the kidney across glomerulus filtration and tubular secretion due to it's own slightly soluble in water properties, CPFX dose must be adjusted in patients with adequate kidney function.(Brunton et al., 2018; Wolfson &Hooper, 1991) . CPFX medication was linked to an elevation in urea serum levels and decrease at creatinine clearance ranging from 0.2 to 1.3 percent in human patients, according to published data. Furthermore, azotaemia rates with ciprofloxacin have been predicted to range between 1.8 and 13.1 per 1000 individuals treated with the drug.

The lack of any identifying clinical symptoms of nephrotoxicity other than an increase in serum urea plus decreasing in creatinine clearance after administration of a fluoroquinolone, on the other hand, necessitates maintaining a high index of suspicion. Acute renal failure caused by CPFX medication has been linked to patients over the age of 50 in nearly all documented cases (Lipsky &Baker, 1999) (Anand, 1993; Lo et al., 1993). According to the findings of this study, CPFX causes oxidative stress and apoptosis in the kidney, which causes tissue damage and a decrease in the glomerular filtration rate, resulting in an accumulation of creatinine and urea in serum samples. (Stojiljković et al., 2008) and damage to kidney tubules (Varzi et al., 2007), An increment in serum creatinine in addition to elevation in serum urea levels was seen in our research., as well as histological changes in kidney structure and haemorrhage, indicating that CPFX causes kidney damage.

There has been a significant surge in scientific researches about the function of natural pharmaceuticals in the therapy of a variety of ailments with fewer side effects than synthetic medications (Balick et al., 2000).Pumpkin is a member of the Cucurbitaceae family. The most common pumpkin species is (cucurbita pepo l.), which is a natural source of unsaturated fatty acids, essential fatty acids-omega 3,6,9, phytosterols, caratonoids, vitamin E, and vitamin A. Consumption of the plants, which contains those compounds in high concentrations, will play a major role in disease prevention. (Eraslan et al., 2013), Because of its antioxidant properties, its seeds could be used as a functional food or medicine. (Murkovic et al., 1996).

The study's purpose was to explore, if pumpkin seeds oil might protect cells against CPFX-induced oxidative stress, tissue damage, and apoptosis. Because of its active antioxidant properties, Pumpkin seed oil defends against mitochondrial dysfunction and cellular destruction caused by CPFX by minimizing hepatocellular membrane lipid oxidation. and preventing tissue damage, which could lead to the leakage

of mitochondrial contents (liver enzyme) into the bloodstream. This is explained by the significant decrease in liver biomarkers such as ALT and AST after PSO administration in combination with CPFX, as compared to CPFX-only treated rats. The administration of CPFX causes an increase in AST and ALT levels (Adikwu &Brambaifa, 2012; Pham et al., 2019).
Furthermore, the recorded redox statistics indicated a positive decrease in liver content MDA, as well as a large enhancement in the anti-oxidant factor GSH in the liver of rats administered PSO in conjunction with CPFX, compared to rats given CPFX alone., indicating Hepato-protective activity and antioxidant role of PSO against CPFX-induced oxidative stress and hepatocellular injury, based on previous studies that showed an increase in MDA and a decrease in GSH mainly after administration of CPFX (Afolabi &Oyewo, 2014; Ketterer et al., 1990). The documented findings correspond to the current research. The ability of PSO to protect against CPFX-induced apoptosis was investigated by seeing such a marked decline in the apoptotic biological markers BAX and TNF in rat plasma and tissue samples given a combination of PSO and CPFX, as well as a big improvement in anti-apoptotic factor BCL2 in liver tissue of rats given only CPFX. Previous research on CPFX-treated humans demonstrated a rise in BAX/BCL2 ratio, indicating apoptotic activity. (Aranha et al., 2000).
According to the findings, the combination of PSO and CPFX indicated a positive decrease in serum creatinine, serum urea, and marked improvement in histopathological specimens when compared to specimens taken from rats given CPFX alone. Because of CPFX capacity to induce oxidative stress and glomerulus tissue destruction, CPFX caused glomerular filtration disorder, resulting in the accumulation of creatinine and urea in the serum and massive changes in kidney tissue.

5. Conclusion

1) The current research adds to the growing body of data about the liver and kidneys injury, ciprofloxacin may damage the cells and induce apoptosis. AS a result, it is advised that in human therapy, liver and kidney function be monitored and doses adjusted according to the patient's condition.
2) The combination of PSO and CPFX protects against CPFX-induced liver and kidney injury due to its antioxidant properties, That Scavenges Free radicals and inhibit apoptosis.

Acknowledgement

The author express thanks Professor. Dr / Ashraf A. A. Elkomy, the head of pharmacological Department and Members of the pharmacology department's stuff, faculty of veterinary medicine at BENHA University. Ass.proffessor Dr/ Enas A.H. Farag Deputy of animal health researchers institute for Regional Laboratories, ass. Professor Dr/ Samir Osman the head of the Pharmacognosy department and the pharmacology department staff at O6U University's Faculty of Pharmacy, Prof. Dr/ Sahar S Abd El-Rahman Pathology department, Faculty of Veterinary Medicine, Cairo University, Giza, Egypt and scientific research department, Egyptian International Pharmaceutical Industries Company – EIPICO, Cairo, Egypt, for their invaluable Advise, and assistance.

Declaration of interest

The author declare no conflict of interest. The author alone are responsible for the content and writing of the paper.
Funding: this research did not receive any specific grant from funding agencies in the public, commercial, or not-for-profit sectors.

References

[1] Adikwu, E., & Brambaifa, N. (2012). Ciprofloxacin cardiotoxicity and hepatotoxicity in humans and animals. https://doi.org/10.4236/pp.2012.32028.
[2] Afolabi, O. K., & Oyewo, E. B. (2014). Effects of ciprofloxacin and levofloxacin administration on some oxidative stress markers in the rat. *Int J Biol Vet Agricult Food Eng, 8*, 31-39.
[3] Al-Naqeeb, M. A., Thomson, M., Al-Qattan, K., Kamel, F., Mustafa, T., & Ali, M. (2003). Biochemical and histopathological toxicity of an aqueous extract of ginger in female rats. *Kuwait journal of science and engineering, 30*(2), 35-48.
[4] AL-Rikaby, A. A., Ghadhban, R. F., & Majeed, S. K. (2016). The effects of ciprofloxacin on male rabbits: Biochemical and histopathological study. *Al-Qadisiyah Journal of Veterinary Medicine Sciences, 15*(1), 38-44.
[5] Amin, T., & Thakur, M. (2013). Research article cucurbita mixta (pumpkin) seeds-a general overview on their health benefits. *Int J Recent Sci Res, 4*(6), 846-854.
[6] Anand, A. (1993). Ciprofloxacin nephrotoxicity. *Archives of internal medicine, 153*(23), 2705-2706. https://doi.org/10.1001/archinte.1993.00410230129017.
[7] Aranha, O., Wood, D. P., & Sarkar, F. H. (2000). Ciprofloxacin mediated cell growth inhibition, S/G2-M cell cycle arrest, and apoptosis in a human transitional cell carcinoma of the bladder cell line. *Clinical Cancer Research, 6*(3), 891-900.
[8] Aranha, O., Zhu, L., Alhasan, S., Wood, D. P., Kuo, T. H., & Sarkar, F. H. (2002). Role of mitochondria in ciprofloxacin induced apoptosis in bladder cancer cells. *The Journal of urology, 167*(3), 1288-1294. https://doi.org/10.1016/S0022-5347(05)65283-4.
[9] Balick, M. J., Kronenberg, F., Ososki, A. L., Reiff, M., Fugh-Berman, A., Bonnie, O. C., . . . Atha, D. (2000). Medicinal plants used by Latino healers for women's health conditions in New York City. *Economic botany, 54*(3), 344-357. https://doi.org/10.1007/BF02864786.
[10] Ballatori, N., Krance, S. M., Notenboom, S., Shi, S., Tieu, K., & Hammond, C. L. (2009). Glutathione dysregulation and the etiology and progression of human diseases. https://doi.org/10.1515/BC.2009.033.
[11] Battino, M., Bullon, P., Wilson, M., & Newman, H. (1999). Oxidative injury and inflammatory periodontal diseases: the challenge of anti-oxidants to free radicals and reactive oxygen species. *Critical Reviews in Oral Biology & Medicine, 10*(4), 458-476. https://doi.org/10.1177/10454411990100040301.
[12] Beutler, E., & Kelly, B. M. (1963). The effect of sodium nitrite on red cell GSH. *Experientia, 19*(2), 96-97. https://doi.org/10.1007/BF02148042.
[13] Brunton, L. L., Chabner, B., & Knollmann, B. C. (2018). *Goodman & Gilman's the pharmacological basis of therapeutics*: McGraw-Hill Education New York, NY, USA:.
[14] Cherubin, C. E., Eng, R. H., Smith, S. M., & Tan, E. N. (1992). A comparison of antimicrobial activity of ofloxacin, L-ofloxacin, and other oral agents for respiratory pathogens. *Diagnostic microbiology and infectious disease, 15*(2), 141-144. https://doi.org/10.1016/0732-8893(92)90038-U.
[15] Council, N. R. (2010). Guide for the care and use of laboratory animals.
[16] Davalos-Misslitz, A. C., Rieckenberg, J., Willenzon, S., Worbs, T., Kremmer, E., Bernhardt, G., & Förster, R. (2007). Generalized multi-organ autoimmunity in CCR7-deficient mice. *European journal of immunology, 37*(3), 613-622. https://doi.org/10.1002/eji.200636656.

[17] Elbe, H., Dogan, Z., Taslidere, E., Cetin, A., & Turkoz, Y. (2016). Beneficial effects of quercetin on renal injury and oxidative stress caused by ciprofloxacin in rats: A histological and biochemical study. *Human & experimental toxicology, 35*(3), 276-281. https://doi.org/10.1177/0960327115584686.
[18] Eraslan, G., Kanbur, M., Aslan, Ö., & Karabacak, M. (2013). The antioxidant effects of pumpkin seed oil on subacute aflatoxin poisoning in mice. *Environmental toxicology, 28*(12), 681-688. https://doi.org/10.1002/tox.20763.
[19] Farombi, E. (2013). Ethanol Extract of Moringa oleifera Leaves Modulates Ciprofloxacin-Induced Oxidant Stress in Testis and Semen of Rats. *Archives of Basic and Applied Medicine, 1*(1), 59-66.
[20] Gajewski, M., Radzanowska, J., Danilcenko, H., Jariene, E., & Cerniauskiene, J. (2008). Quality of pumpkin cultivars in relation to sensory characteristics. *Notulae Botanicae Horti Agrobotanici Cluj-Napoca, 36*(1), 73-79.
[21] Gomes, M. P., Gonçalves, C. A., de Brito, J. C. M., Souza, A. M., da Silva Cruz, F. V., Bicalho, E. M., . . . Garcia, Q. S. (2017). Ciprofloxacin induces oxidative stress in duckweed (Lemna minor L.): implications for energy metabolism and antibiotic-uptake ability. *Journal of hazardous materials, 328*, 140-149. https://doi.org/10.1016/j.jhazmat.2017.01.005.
[22] Hasanuzzaman, M., Bhuyan, M., Anee, T. I., Parvin, K., Nahar, K., Mahmud, J. A., & Fujita, M. (2019). Regulation of ascorbate-glutathione pathway in mitigating oxidative damage in plants under abiotic stress. *Antioxidants, 8*(9), 384. https://doi.org/10.3390/antiox8090384.
[23] Hemieda, F. A., El-Kholy, W. M., & Masud, A. S. A. (2019). Evaluating the protective impact of ginger extract against ciprofloxacin-induced hepatotoxicity in male albino rats. *IOSR Journal of Pharmacy and Biological Sciences, 14*(1), 23-30.
[24] Hwang, Y. P., Choi, C. Y., Chung, Y. C., Jeon, S. S., & Jeong, H. G. (2007). Protective effects of puerarin on carbon tetrachloride-induced hepatotoxicity. *Archives of pharmacal research, 30*(10), 1309-1317. https://doi.org/10.1007/BF02980272.
[25] K Ramadan, B., A Mohammad, S., S Mahmoud, E., & A Ouda, E. (2016). ROLE OF PUMPKIN SEED OIL ON SOME CARDIOVASCULAR AND RENAL ASPECTS IN ADULT MALE ALBINO RATS. *Al-Azhar Medical Journal, 45*(4), 931-956. https://doi.org/10.12816/0034755.
[26] Kehrer, J., Robertson, J., & Smith, C. (2010). Free radicals and reactive oxygen species. https://doi.org/10.1016/B978-0-08-046884-6.00114-7.
[27] Ketterer, B., Meyer, D., Taylor, J., Pemble, S., Coles, B., & Fraser, G. (1990). GSTs and protection against oxidative stress. *Glutathione S-transferase and drug resistance. London: Taylor and Frances, 109*.
[28] Khaki, A., Heidari, M., Novin, M. G., & Khaki, A. A. (2008). Adverse effects of ciprofloxacin on testis apoptosis and sperm parameters in rats. *Iranian Journal of Reproductive Medicine, 6*(2), 71-76.
[29] Kroemer, G., Galluzzi, L., & Brenner, C. (2007). Mitochondrial membrane permeabilization in cell death. *Physiological reviews, 87*(1), 99-163. https://doi.org/10.1152/physrev.00013.2006.
[30] Levinson, S. S. (1978). Kinetic centrifugal analyzer and manual determination of serum urea nitrogen, with use of o-phthaldialdehyde reagent. *Clinical chemistry, 24*(12), 2199-2202. https://doi.org/10.1093/clinchem/24.12.2199.
[31] Lim, E. J., Yoon, Y. J., Heo, J., Lee, T. H., & Kim, Y.-H. (2018). Ciprofloxacin enhances TRAIL-induced apoptosis in lung cancer cells by upregulating the expression and protein stability of death receptors through CHOP expression. *International journal of molecular sciences, 19*(10), 3187. https://doi.org/10.3390/ijms19103187.
[32] Lipsky, B. A., & Baker, C. A. (1999). Fluoroquinolone toxicity profiles: a review focusing on newer agents. *Clinical Infectious Diseases, 28*(2), 352-361. https://doi.org/10.1086/515104.
[33] Lo, W. K., Rolston, K. V., Rubenstein, E. B., & Bodey, G. P. (1993). Ciprofloxacin-induced nephrotoxicity in patients with cancer. *Archives of internal medicine, 153*(10), 1258-1262. https://doi.org/10.1001/archinte.1993.00410100082012.
[34] Main, P. A., Angley, M. T., O'Doherty, C. E., Thomas, P., & Fenech, M. (2012). The potential role of the antioxidant and detoxification properties of glutathione in autism spectrum disorders: a systematic review and meta-analysis. *Nutrition & metabolism, 9*(1), 1-37. https://doi.org/10.1186/1743-7075-9-35.
[35] Murkovic, M., Hillebrand, A., Winkler, J., Leitner, E., & Pfannhauser, W. (1996). Variability of fatty acid content in pumpkin seeds (Cucurbita pepo L.). *Zeitschrift für Lebensmittel-Untersuchung und Forschung, 203*(3), 216-219. https://doi.org/10.1007/BF01192866.
[36] Ohkawa, H., Ohishi, N., & Yagi, K. (1979). Assay for lipid peroxides in animal tissues by thiobarbituric acid reaction. *Analytical biochemistry, 95*(2), 351-358. https://doi.org/10.1016/0003-2697(79)90738-3.
[37] Papich, M. G. (1998). Antibacterial drug therapy: focus on new drugs. *Veterinary Clinics of North America: Small Animal Practice, 28*(2), 215-231. https://doi.org/10.1016/S0195-5616(98)82002-0.
[38] Patlevič, P., Vašková, J., Švorc Jr, P., Vaško, L., & Švorc, P. (2016). Reactive oxygen species and antioxidant defense in human gastrointestinal diseases. *Integrative medicine research, 5*(4), 250-258. https://doi.org/10.1016/j.imr.2016.07.004.
[39] Pham, T. D., Ziora, Z. M., & Blaskovich, M. A. (2019). Quinolone antibiotics. *MedChemComm, 10*(10), 1719-1739. https://doi.org/10.1039/C9MD00120D.
[40] Prast-Nielsen, S., Huang, H.-H., & Williams, D. L. (2011). Thioredoxin glutathione reductase: its role in redox biology and potential as a target for drugs against neglected diseases. *Biochimica et Biophysica Acta (BBA)-General Subjects, 1810*(12), 1262-1271. https://doi.org/10.1016/j.bbagen.2011.06.024.
[41] Rabrenović, B. B., Dimić, E. B., Novaković, M. M., Tešević, V. V., & Basić, Z. N. (2014). The most important bioactive components of cold pressed oil from different pumpkin (Cucurbita pepo L.) seeds. *LWT-Food Science and Technology, 55*(2), 521-527. https://doi.org/10.1016/j.lwt.2013.10.019.
[42] Reitman, S., & Frankel, S. (1957). Determination of glutamate-pyruvate transaminase (ALT) and aspartate aminotransfrase (AST). *J Clin Pathol, 28*, 56. https://doi.org/10.1093/ajcp/28.1.56.
[43] Retnam, K. R., & Martin, P. (2006). *Ethnomedicinal plants*: Jodhpur.
[44] Rizzato, G., & Allegra, L. (1997). Efficacy and tolerability of a teicoplanin-ciprofloxacin combination in severe community-acquired pneumonia. *Clinical drug investigation, 14*(5), 337-345. https://doi.org/10.2165/00044011-199714050-00001.
[45] Snezhkina, A. V., Kudryavtseva, A. V., Kardymon, O. L., Savvateeva, M. V., Melnikova, N. V., Krasnov, G. S., & Dmitriev, A. A. (2019). ROS generation and antioxidant defense systems in normal and malignant cells. *Oxidative medicine and cellular longevity, 2019*. https://doi.org/10.1155/2019/6175804.
[46] Stojiljković, N., Veljković, S., Mihailović, D., Stoiljković, M., Radovanović, D., & Ranđelović, P. (2008). The effect of calcium channel blocker verapamil on gentamicin nephrotoxicity in rats. *Bosnian journal of basic medical sciences, 8*(2), 170. https://doi.org/10.17305/bjbms.2008.2977.
[47] Taslidere, E., Dogan, Z., Elbe, H., Vardi, N., Cetin, A., & Turkoz, Y. (2016). Quercetin protection against ciprofloxacin induced liver damage in rats. *Biotechnic & Histochemistry, 91*(2), 116-121. https://doi.org/10.3109/10520295.2015.1085093.
[48] Varzi, H., Esmailzadeh, S., Morovvati, H., Avizeh, R., Shahriari, A., & Givi, M. (2007). Effect of silymarin and vitamin E on gentamicin-induced nephrotoxicity in dogs. *Journal of veterinary pharmacology and therapeutics, 30*(5), 477-481. https://doi.org/10.1111/j.1365-2885.2007.00901.x.
[49] Weyers, A. I., Ugnia, L. I., Ovando, H. G., & Gorla, N. B. (2002). Ciprofloxacin increases hepatic and renal lipid hydroperoxides levels in mice. *Biocell, 26*(2), 225. https://doi.org/10.32604/biocell.2002.26.225.
[50] Wolfson, J., & Hooper, D. (1991). Pharmacokinetics of quinolones: newer aspects. *European Journal of Clinical Microbiology and Infectious Diseases, 10*(4), 267-274. https://doi.org/10.1007/BF01967000.
[51] Wright, M. E., Wong, A. T., Levitt, D., Parrag, I. C., Yang, M., & Santerre, J. P. (2018). Influence of ciprofloxacin-based additives on the hydrolysis of nanofiber polyurethane membranes. *Journal of Biomedical Materials Research Part A, 106*(5), 1211-1222. https://doi.org/10.1002/jbm.a.36318.
[52] Yeh, S.-H., Lin, C.-H., Lee, C.-F., & Gean, P.-W. (2002). A requirement of nuclear factor-κB activation in fear-potentiated startle. *Journal of Biological Chemistry, 277*(48), 46720-46729. https://doi.org/10.1074/jbc.M206258200.

[i] Gamma Glutamyl Transferase
[ii] Alkaline Phosphatase

[iii] Protein Carbonyl
[iv] Hydrogen Peroxide
[v] Nitric Oxide
[vi] Superoxide Dismutase
[vii] Catalase
[viii] Glutathione Peroxidase
[ix] Glutathione Reductase
[x] Pumpkin Seeds