International Journal of Engineering & Technology, 7 (3.33) (2018) 1-3

International Journal of Engineering & Technology

Website: www.sciencepubco.com/index.php/IJET

Research paper



Right Ventricle Segmentation from Heart using Active Contour Model without Edge and Split Plane Decision

Ho Chul Kang

SungKongHoe University, Seoul, Korea
**Corresponding author E-mail: E-mail: hckang@skhu.ac.kr*

Abstract

In this paper, we propose an automatic segmentation method of right ventricle from computed tomography angiography (CTA) using Chan-Vese model and split plane detection. First, we remove noise in the images by applying anisotropic diffusion filter and extract the whole heart using Otsu Thresholding. Second, the volume of interest (VOI) is detected by Chan-Vese model and morpholotical operation. Third, we divide the heart to left and right region using power watershed. Finally we detect split plane which divide right heart to right ventricle and atrium. We tested our method in ten CT images and they were obtained from a different patient. For the evaluation of the computational performance of the proposed method, we measured the total processing time. The average of total processing time, from first step to third step, was 13.92±1.28 s. We expect for our method to be used in cardiac diagnosis for cardiologist.

Keywords: *Image segmentation, heart segmentation, right ventricle segmentation, Active Contour Model without edge, Chan-Vese model, split plane detection, power watershed*

1. Introduction

Image segmentation [1] is to extract specific region from the image. There are two methods of segmentation, top-bottom and bottom-up approach. Top-bottom is to divide the whole image to the part, and bottom-up is to detect regions from the part to the whole region. In the field of medicine, it is necessary to detect some organs or tumors from medical images for diagnosis. Computed tomography (CT) is an imaging procedure that uses x-ray technology to produce tomographic images of specific object. CT distinguishes bones better than organic tissues. The muscle and the cavities of the specific organ are not well differentiated, both appearing on close gray tones on the CT scan. CTA, CT angiography and one of medical images which have the information of the heart, is widely used in image segmentation [1] because it provides more detailed anatomic information about the organ. The disorders of the heart of blood vessels often cause cardiovascular diseases [2], and heart segmentation from CTA has been used for cardiac diagnosis.

Several approaches for the automatic heart segmentation have been proposed. Olivier et al. [3] presented a heart segmentation method using an iterative Chan-Vese algorithm [4]. They used L1 fidelity term for the computational efficiency instead of L2 fidelity which is classic term. However, this approach extracted only the whole heart, so it is difficult to extract only left ventricle from CTA. Ecabert et al. [5] proposed automatic segmentation of four chambers by using statistical geometry model and training meshes from cardiac CTA images. This method required well-defined training data sets, too much time and effort to generate a template mesh. Avendi et al. [6] proposed automatic segmentation of the right ventricle from cardiac MRI. This method is based on machine learning, i.e. deep learning, so many training data and offline training stages are necessary. Punithakumar et al. [7] proposed right ventricular segmentation in cardiac MRI. This method is based on moving mesh correspondences. So template 3d mesh is necessary. Atehortúa et al. [8] proposed automatic segmentation of right ventricle in cardiac MRI. They segment right ventricle using a saliency analysis. This method localize heart and segment endocardium.

In this paper, we propose an automatic method to extract the right ventricle in CTA using Chan-Vese [4] and split plane detection which we develop without any training data sets and template meshes. The remainder of the paper is organized as follows. The next section describes the proposed method of automatic segmentation of the right ventricle in cardiac CTA. This procedure consists of four processing steps. Section 3 presents the results of the proposed method to clinical dataset. In section 4, we summarize the results and discussion.

2. Methods

An easy way to comply with the paper formatting requirements is to use this document as a template and simply type your text into it.
Your paper must use a page size corresponding to A4 which is 21cm wide and 29.7cm long. The margins must be set as follows:
Top = 1.5cm
Bottom = 1.5cm
Left =2cm
Right=1.5cm
Your paper must be in two column format with a space of 0.5cm between columns.

2.1. Pre-Processing and Extracting the Whole Heart

First, we smooth the input image by removing noise. In general, there is much noise in the cardiac CTA and it would not be vivid.

Copyright © 2018 Authors. This is an open access article distributed under the Creative Commons Attribution License, which permits unrestricted use, distribution, and reproduction in any medium, provided the original work is properly cited.

So image smoothing is essential to segment heart region. There are many denosing methods, Gaussian filtering, median filtering, bilateral filtering, anisotropic diffusion filtering [9] and so on [1]. Figure 1 shows the result of several image denosing. Among them, we use anisotropic diffusion filtering [7], which minimize total variation (TV), to preserve the edge while smoothing the original image and preserves finer detailed structures in images. The equation of anisotropic diffusion filter is as follows.

$$\min TV = \int_{\Omega} \sqrt{u_x^2 + u_y^2}\, dxdy \tag{1}$$

where u is an image, ux and uy is the derivative of u w.r.t. x and y respectively. To discretize and optimize this equation, Rudin et al. [8] proposed a method to minimize using gradient descent PDE. Through calculus of variations, the gradient descent PDE of the minimization is as follows.

$$\begin{cases} \partial_t u = \operatorname{div} \frac{\nabla u}{|\nabla u|} + \lambda(f-u), \\ \nu \cdot \nabla u = 0 \quad \text{on } \partial\Omega. \end{cases} \tag{2}$$

Since this equation is convex, the steady state solution of the gradient descent is the global optimum. And gradient descent is performed by iterating equation (3).

$$u_{i,j}^{n+1} = u_{i,j}^{n} + dt\Big[\nabla_x^- \Big(\frac{\nabla_x^+ u_{i,j}^n}{\sqrt{(\nabla_x^+ u_{i,j}^n)^2 + (m(\nabla_y^+ u_{i,j}^n, \nabla_y^- u_{i,j}^n))^2}}\Big) + \nabla_y^- \Big(\frac{\nabla_y^+ u_{i,j}^n}{\sqrt{(\nabla_y^+ u_{i,j}^n)^2 + (m(\nabla_x^+ u_{i,j}^n, \nabla_x^- u_{i,j}^n))^2}}\Big)\Big] + dt\lambda(f_{i,j} - u_{i,j}^n), \quad i,j = 1,\ldots,N-1 \tag{3}$$

And we extracts the whole heart including the left and right heart region using Otsu thresholding [11] and connected component labeling [1]. And we expand the heart region by comparing the mean CT value of each cluster. So the clusters are removed as cardiac muscles and the other clusters are merged. To increase accuracy, we apply morphology operation, i.e. open [1]. (see Figure 2).

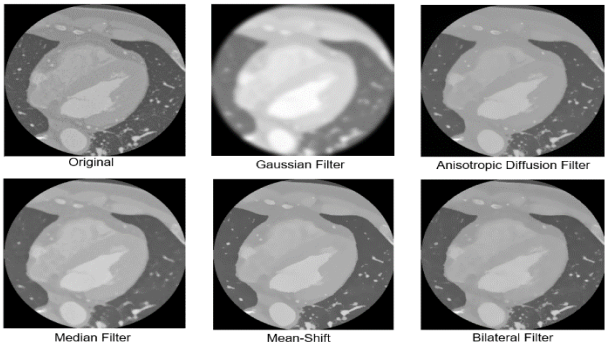

Fig 1: The denoised images. Gaussian, median bilateral, AD filtering and mean-shift [10].

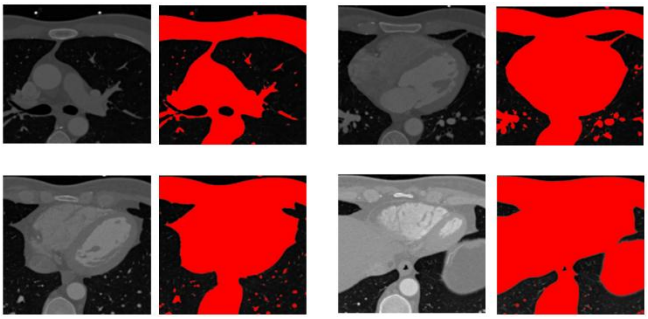

Fig. 2: The result of the whole heart extraction. The input image (left) and the result of segmentation (right) in each image.

2.2. VOI Detection

In this step, we segment the left and right sides of the heart accurately using the previous rough segmentation results with Chan-Vese model [4] which is the one of the most famous region-based segmentation. In region-based segmentation, global image statistics are considered in the entire image. The Chan-Vese energy function is defined as follows:

$$E_{CV}(F, c_1, c_2) = \int_F |g - c_1|^2\, dx + \int_{\Omega \setminus F} |g - c_2|^2\, dx + \mathcal{H}^{N-1}(\partial F \cap \Omega). \tag{4}$$

And the level set approach of this energy is defined as follows:

$$E_{CV}(\phi, c_1, c_2) = \lambda \int_{\Omega} |g - c_1|^2 (1 - H(\phi))\, dx + \lambda \int_{\Omega} |g - c_2|^2 H(\phi)\, dx + \mu \int_{\Omega} |DH(\phi)|\, dx \tag{5}$$

$$E_{CV}(F, c_1, c_2) = \int_F |g - c_1|^2\, dx + \int_{\Omega \setminus F} |g - c_2|^2\, dx + \mathcal{H}^{N-1}(\partial F \cap \Omega).$$

$$E_{CV}(F, c_1, c_2) = \int_F |g - c_1|^2\, dx + \int_{\Omega \setminus F} |g - c_2|^2\, dx + \mathcal{H}^{N-1}(\partial F \cap \Omega).$$

$$E_{CV}(F, c_1, c_2) = \int_F |g - c_1|^2\, dx + \int_{\Omega \setminus F} |g - c_2|^2\, dx + \mathcal{H}^{N-1}(\partial F \cap \Omega).$$

To optimize this energy, we use Euler-Lagrange equation and apply this numerical solution.

$$\begin{aligned} \phi_{i,j}^{n+1} = \phi_{i,j}^n + \Delta t \delta_\epsilon(\phi_{i,j})[&d_1(\phi_{i+1,j}^n - \phi_{i,j}^n) + d_2(\phi_{i,j}^n - \phi_{i-1,j}^n) \\ &+ d_3(\phi_{i,j+1}^n - \phi_{i,j}^n) + d_4(\phi_{i,j}^n - \phi_{i,j-1}^n) \\ &+ \lambda\left((g - c_1)^2 - (g - c_2)^2\right)]. \end{aligned} \tag{6}$$

Figure 3 shows the result of heart segmentation.

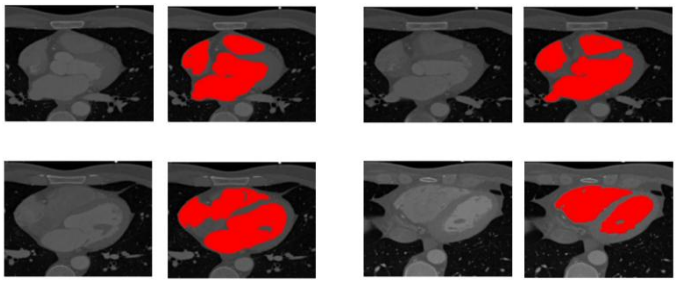

Fig. 3: The result of Applying Chan-Vese model. The input image (left) and the result of segmentation (right) in each image.

2.3. Division of Left and Right Heart

In this step, we split the whole heart into left and right sides. The left side of the heart consists of the left ventricle (LV) and left atrium (LA). The right side consists of the right ventricle (RV) and right atrium (RA). Anatomically, the LV and RV are separately located in the lower slices whereas the LA and RA are not that easily distinguished in the upper slices due to the ambiguity in the boundaries between the left and right sides of heart. In our study, we first detect the seed of the LV and RV in the lower axial slices. Then, we apply a power watershed [12], which is a tool used to segment an object with weak boundaries, to separate the heart to left and right. Figure 4 shows the result of separating left and right heart.

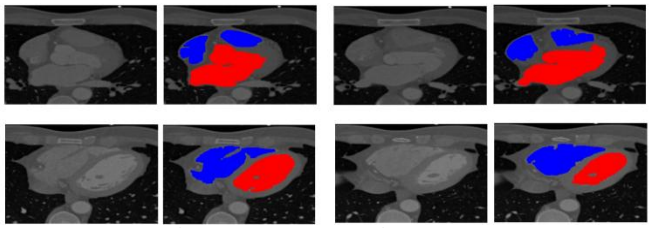

Fig. 4: The result of heart separation to left and right. The input image (left) and the result of separation (right) in each image.

2.4. Removing Left Heart and Deciding Split Plane

In this step, we remove the left heart, i.e. left ventricle and atrium. In previous step, we divide left and right heart, so we only check the y-position of two heart, left and right heart. The upper heart is the right heart and the lower one is the left ventricle. So we leave only the upper heart, i.e. right ventricle and atrium. To extract only right ventricle, we detect split plane which separate the right heart to ventricle and atrium. To decide the split plane, we use a plane equation.

Plane equation: $ax + by + cz + d = 0;$ (7)

Where, vector (a, b, c) is the normal vector of this plane, and (x0, y0, z0) belongs to this plane. This point is the center of right heart. To obtain the normal vector and the center point, we use split energy function which is composed of area term and intensity term [13].

3. Results and Discussion

We tested our method using the system which has the Intel® Core™2 Quad 3.4 GHz processor, 16 GB of main memory and Windows 10. We extract the left and right heart from ten CT images and they were obtained from a different patient. The numbers of images per scan ranged from 192 to 227. Each image had a matrix size of 512 × 512. The voxel size was 0.36. Figure 5 shows the result of split plane detection which separate right ventricle and atrium and Figure 6 shows the result of right ventricle segmentation. Table 1 shows the computational time for each step. For the evaluation of the computational performance of the proposed method, we measured the total processing time. The average of total processing time, from first step to third step, was 13.92±1.28 s.

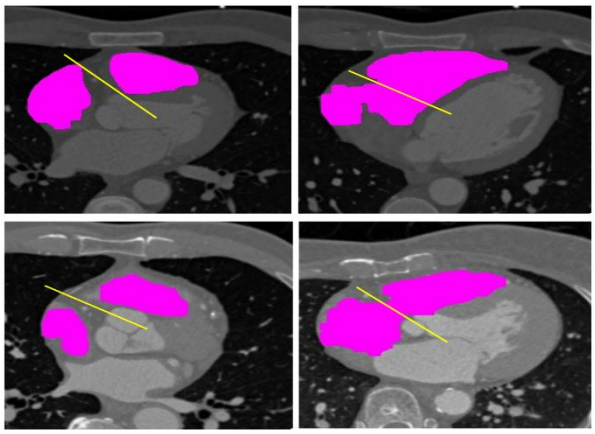

Fig. 5: The result of split plane detection. The yellow line is the plane

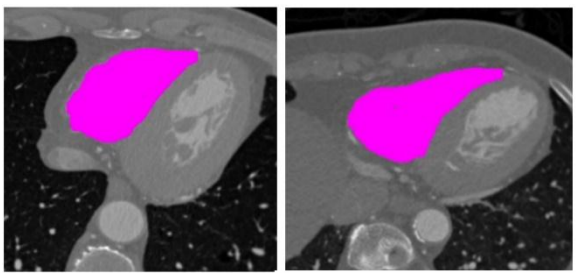

Fig. 6: The result of right ventricle segmentation. The pink region is the right ventricle.

Table 1: Computational Time for Each Segmentation Step (sec)

Data	Pre-processing and whole heart	VOI detection	Division of left and right heart	Detection of split plane	Total
1	3.8	6.9	1.1	0.4	12.2
2	4.6	7.2	2.3	0.3	14.4
3	4.1	6.7	1.2	0.4	12.4
4	5.4	7.6	2.1	0.4	15.5
5	4.4	7.2	2.0	0.3	13.9
6	5.9	7.9	1.4	0.5	15.7
7	3.6	7.5	1.3	0.3	12.7
8	4.9	7.3	1.1	0.2	13.5
9	5.6	7.9	1.8	0.4	15.7
10	4.6	6.8	1.5	0.3	13.2

It is difficult to segment the heart, especially left and right ventricle, because the chambers of the heart have weak edge or no edge. In this paper, we presented a segmentation method of the right ventricle region using Chan-Vese model and split plane detection by split energy function. Right ventricle is significant to diagnosis cardiovascular disease for several years. So this study is expected to be used in cardiac diagnosis for cardiovascular disease.

Acknowledgement

This research was supported by Basic Science Research Program through the National Research Foundation of Korea (NRF) funded by the Ministry of Science, ICT & Future Planning (NRF-2017R1C1B5017738) in 2017.

References

[1]]R.C. Gonzalez, R.E. Woods, and S.L. Eddins, Digital image processing using MATLAB, Person Prentice Hall, pp. 200-250, 2004.
[2] W. H. O. Director-General, "The World Health Report: Report of the Director-General," World Health Organization, 2003.
[3] O. Rousseau, and Y. Bourgault, "Heart segmentation with an iterative Chan-Vese algorithm," HAL, 2008.
[4] T. F. Chan, and L. A. Vese, "Active contours without edges," IEEE Transactions on Image Processing, Vol. 10, No. 2, pp. 266-277, 2001.
[5] O. Ecabert, J. Peters, H. Schramm, C. Lorenz, J. von Berg, M. J. Walker, M. Vembar, M. E. Olszewski, K. Subramanyan, and G. Lavi, "Automatic model-based segmentation of the heart in CT images," IEEE Transactions on Medical Imaging, Vol. 27, No. 9, pp. 1189-1201, 2008.
[6] M. R. Avendi, A. Kheradvar and H. Jafarkhani, "Automatic segmentation of the right ventricle from cardiac MRI using a learning-based approach," Magnetic Resonance in Medicine, Vol.78, No.6, pp.2439-2448, Feb 2017.
[7] K. Punithakumar, M. Noga, I. B. Ayed and P. Boulanger, "Right ventricular segmentation in cardiac MRI with moving mesh correspondences," Computerized Medical Imaging and Graphics, Vol.43, pp. 15-25, July 2015.
[8] A. Atehortúa, M.A. Zuluaga, J.D. Garcia and E. Romero, "Automatic segmentation of right ventricle in cardiac cine MR images using a saliency analysis," Medical Physics, Vol. 43, No. 12, pp. 62-70, Dec 2016.
[9] I.R. Leonid, O. Stanley, and F. Emad, "Nonlinear total variation based noise removal algorithms," Physica D, Vol. 60, No. 1-4, pp. 259-268, Nov 1992.
[10] F. Hosotani, Y. Inuzuka, M. Hasegawa, S. Hirobayashi and T. Misawa, "Image Denoising With Edge-Preserving and Segmentation Based on Mask NHA," IEEE Transaction on Image Processing, Vol. 24, No. 12, pp. 6025-6033, Dec 2015.
[11] N. Otsu, "A threshold selection method from gray-level histograms," IEEE Transactions on Systems, Man, and Cybernetics, Vol. 9, No. 1, pp. 62-66, Jan 1979.
[12] C. Couprie, L. Grady and L. Najman, "Power Watershed: A Unifying Graph-Based Optimization Framework," IEEE Transactions on Pattern Analysis and Machine Intelligence, Vol. 33, No. 7, pp. 1384-1399, Nov 2010.
[13] H.C. Kang, B. Kim, J. Lee, J. Shin and Y. Shin, "Accurate Four-Chamber Segmentation Using Gradient-Assisted Localized Active Contour Model," Journal of Medical Imaging and Health Informatics, Vol. 5, No. 1, pp. 1-12, Feb 2015.