

Analyzing ovarian tumor and cancer cells using image processing algorithms K means & fuzzy C-means

Thangamma N. G^{1*}, Dr. S. Prasanna²

¹ Department of Computing Science, VISTAS, Chennai, India

² Professor, Department of MCA, VISTAS, Chennai, India

*Corresponding author E-mail: Prasanna.scs@velsuniv.ac.in

Abstract

Ovarian growth is a tumor that occurs in the ovaries of the women. Sometimes, it may derive to be a malignant tumor. Those tumors are acute cancer cells that could be life-threatening if the treatment had not been properly taken. Few of the cases, malignant tumors can be re-moved using surgery or by means of radiations..There is a chance of cancer if not properly removed and they could grow back. Analyzing ovarian cancer is found to be the highest mortality rate of all categories of cancers affecting the women. Considering its malignant effect necessary remedial actions need to be carried out for the welfare of the peoples in the future. Researches and various analysis are being car-ried out to overcome the drastic effect of malignant tumor. Supporting the research, in this paper we have analyzed various imaging modali-ties to examine segmentation and texture analysis with the help of K-Means and Fuzzy C-Means.

Keywords: Clustering; Image Processing Techniques; Ovarian Cancer; Segmentation

1. Introduction

Ovarian cancer is found to be the highest mortality rate of all categories of cancers affecting the women. methodologies, an ultrasound scan is considered for ovarian cancer assessment. Here the image analyzing approach, interpret the images in subjective and observer dependent. In order to compensate this problem, segmentation is considered for the evaluation purpose. This segmentation technique provides necessary data for diagnosis and analysis[1]. To execute a number successful segmentation techniques is reported, in which the effective K-Means and Fuzzy C-Means algorithm has been used to characterize an ovarian lesion from ultrasound Images. The concept of introducing texture analysis as well as segmentation in the health domain would not replace the conventional method of analyzing images, but it is used to aid clinicians in making their diagnoses more effectively [3].

1.1. Ultrasound image of an ovary

Ultrasound imaging is the prominent methodology generally utilized for the representation of women ovary with the point of uncovering different phases of follicular improvement for ripeness treatment, distinguish beginning periods of Polycystic Ovarian Syndrome (PCOS) and ovarian cancer [4]. The generally utilization of ultrasound machine is because of its non-obtrusive nature, effectiveness to utilize, more affordable and also it is effortless and caused less uneasiness contrasted with other imaging modalities [5]. Be that as it may, exact elucidations of these pictures by medicinal specialists are constantly troublesome because of the nearness of picture curios and spot commotions [5]. This is on account of ovary contains tissues, veins, and endometrium which is all top turned during the time spent ultrasound filtering [6].

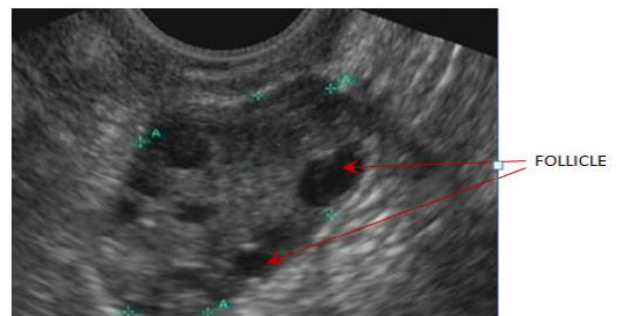

Fig. 1: Ultrasound Image of an Ovary.

Ultrasound pictures give reverberate surface example that describe diverse surface data of articles in the picture [8]. Surface examination gives urgent data that cannot be acquired from manual and visual understanding of the ultrasound pictures of the ovary [9]. Follicles show up as dim spots inhomogeneous locales as opposed to different items that seem brighter in the ultrasound picture of the ovary as appeared in Figure 1. In this way, follicles exhibit unmistakable surface highlights unique in relation to non-follicles [10].

1.2. US technical aspect

US Technical Aspect the sonographic highlights talked about in this record, and the subsequent procedures, require that an in fact sufficient pelvic US be prepared has been got. Regularly this includes transvaginal US, with transabdominal US as needed, and requires that the total blister be capability imaged. We respect that, for a considerable amount of reasons, there might be periodic occasions where a sufficient US study cannot be acquired. On this case, safe portrayal of the kind of blister won't not be do able with US. Shading or power Doppler. US is required for investigation of

most mind boggling sores to ensure that no steady components are blessing (that may show up hypochoic on dim scale depictions and now not be renowned as steady), and to assess for the nearness or nonattendance of take the path of least resistance inside any apparently strong regions or septations. Shading or force Doppler US requires fitting procedure to limit mistaken interpretation. Various parameters, together with accomplish what's more, beat reiteration recurrence, must be upgraded to watch moderate accept circumstances for what they are. In a few examples, practically identical to when shading or power Doppler imaging exhibits little foci of shading as an option than one of kind vessels, ghastly Doppler imaging must be performed to recognize drift from commotion or antiquity. A ton has been composed about utilization of pulsatility record and resistive list in recognizing generous and threatening adnexal masses. All things considered, the affectability and specificity of limit phantom Doppler esteems are not adequately superior to these of morphologic examination for proposal of utilization of these parameters. It was at one time the consenses sentiment inside the gathering that nearness of float in a wonderful perspective was the principle Doppler highlight. We also appreciate that estimations of blisters in three measurements can be altered by method for strain with the vaginal test and that there's fluctuation in exactness of measurements. Mean or most extreme diameters were utilized dynamically in distributed surveys. The specialists selected to utilize most extreme measurement of the blister in our recommendations.

2. Methodology

For the segmentation and analysis of the malignant tumor K – Means and Fuzzy C-Means Technique has been utilized. Here, the segmented tissue region based on K-Means Clustering algorithm and Fuzzy C Means clustering Technique were displayed and discussed.

2.1. K-means clustering

In this algorithm the general instructions, $A = \text{imread}(\text{filename})$ reads the input image from the file specified by filename, referring the format of the file from its source. If filename is a multi-image file, then imread reads the first image in the file.

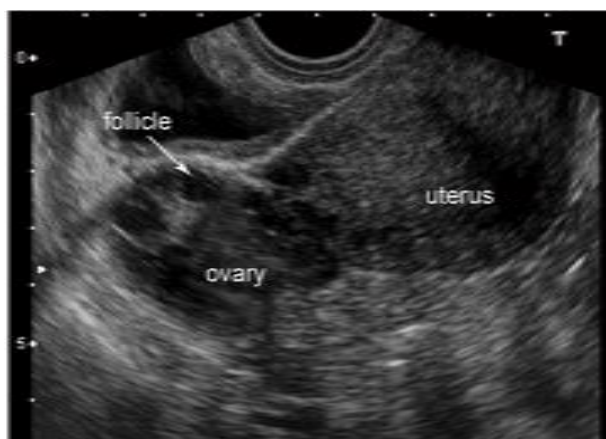


Fig. 2: Test Input Image.

In algorithm to display the image the imshow function has been used. The Image Viewer app presents all of the image display capabilities of imshow but also provides access to a number of other instruments for navigating and exploring pix, similar to scroll bars, the Pixel area device, snapshot understanding software, and the contrast Adjustment software.

3	0.41	0.38	0.36	0.36	0.32	0.33	0.34	0.35	0.3
6	0.44	0.40	0.38	0.37	0.33	0.33	0.34	0.36	0.3
9	0.48	0.44	0.40	0.38	0.33	0.34	0.35	0.36	0.3
0	0.50	0.47	0.42	0.39	0.35	0.35	0.35	0.36	0.3
1	0.51	0.49	0.44	0.40	0.36	0.36	0.36	0.36	0.3
0	0.50	0.48	0.44	0.40	0.36	0.36	0.36	0.36	0.3
8	0.46	0.45	0.43	0.40	0.36	0.36	0.37	0.36	0.3
7	0.44	0.42	0.40	0.39	0.36	0.36	0.37	0.36	0.3

Fig. 3: Pixel Information in Input Image.

2.2. Fuzzy C means clustering

In this technique, the complex Euclidean distance metric was considered. The proposed method was used to group a given data set into a set of different geometric structural clusters. This algorithm is used to carry out interpretation based on the distance between different input data points. The clusters are framed in accordance with the distance between data points and the cluster centers [11].

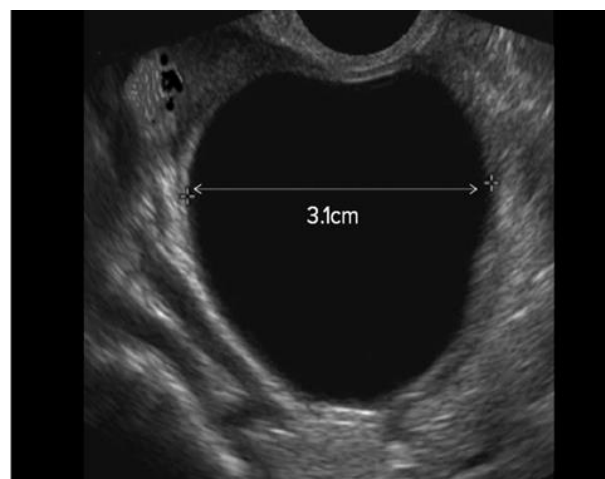
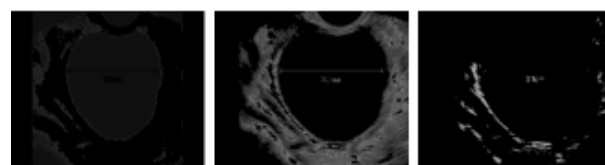


Fig. 4: Sample Input Image.

The Fuzzy C-Means Algorithm is similar to the K –Means Algorithm:

- Step: One Choose a number of clusters. $k=3$
- Step: Two Assign randomly to each point coefficients for being in the clusters
- Step: 3 Repeat until the algorithm has converged (that is, the coefficients' change between two iterations is no more than, the given sensitivity threshold
- Compute the centroid for each cluster.
- For each point, compute its coefficients of being in the clusters.



cluster1=0 cluster2=0.32 cluster3=0.65

Fig. 5: Fuzzy C-Mean Output.

This FCM algorithm was the extension of the K-means algorithm. This is insensitive to the noise which will provide a better result

than the K-means algorithm. In this case also the number of iterations will provide better results.

2.3. Evolution result

The result of two case studies has been analyzed and image report has been provided here Segmented Regions on Various Images of Ovarian Cancer:

A woman in the age of 61 years was taken in the analysis who has a small tumorslowlygrowing, no painful, size of about one egg detected at right inguinal scarp .Clinical palpation wasubcutaneous, fixed, to the deepest layer. Ultrasound scan was performed, it was a round mass, dimension of 5 cm in diameter, wellbo dered, inside of constitution used to be solid and in homogeneous [12].

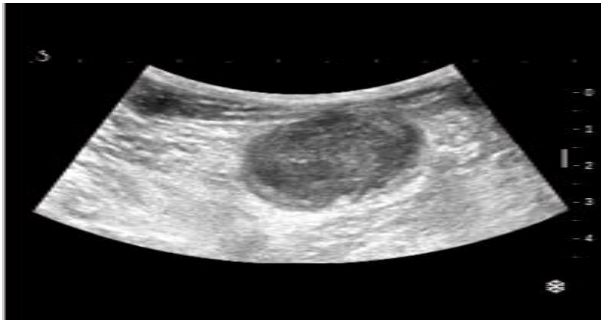
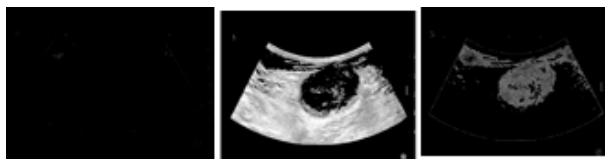

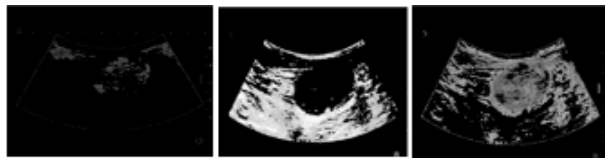Fig. 6: Scan Image Report.

K-Means Clustering



cluster1=0 cluster2=0.30 cluster3=0.65

Fig. 7: K-Means Output.



cluster1=0.1 cluster2=0.30 cluster3=0.65

Fig. 8: Fuzzy C- Mean Output.

Another woman of age 50 years who is having vaginal bleeding had been scanned and image analyzing been carried out. In the scanned report it is found that one mass cystic, multiloculated with septation thickening and solid [13].

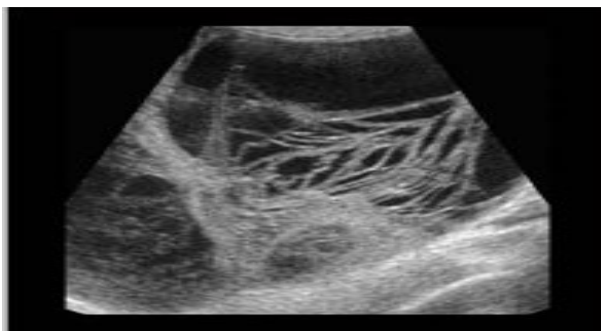
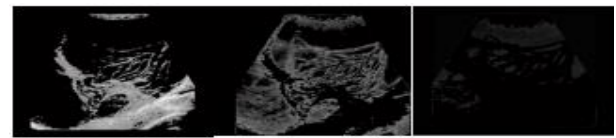

Fig. 9: Input Image.

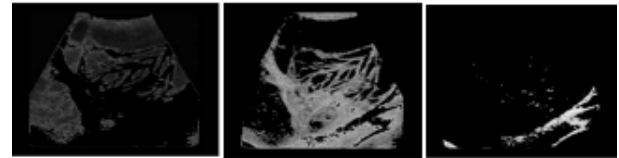
K-Means Clustering:



cluster1=0 cluster2=0.30 cluster3=0.65

Fig. 10: K-Means Output.

Fuzzy C Means Clustering:



cluster1=0.1 cluster2=0.30 cluster3=0.65

Fig. 11: Fuzzy C- Means Output.

3. Conclusion

In the health sector, diagnosing as well as analyzing the tumors in various parts of the body is found to be a challenging task. Research has found to be emerging to make it comfortable to examine in an effective approach. Here we have analyzed ovarian cancer using two important clustering algorithms, namely centroid based K-Means and representative object based Fuzzy C-Means clustering algorithms for precise diagnosis and effective analysis

References

- [1] Dr. Ioannis Hatzipeteros, M.D, Novel Biomarkers In The Diagnosis Of Ovarian Cancer University of Pecs, Faculty of Medicine, Clinical Center Obstetrics and Gynecology Clinic Pecs, Hungary, 2014.
- [2] Monica L. Andersen, Tathiana F. Alvarenga, Renata Mazarro-Costa, Helena C. Hachul, Sergio Tufik, The association of testosterone, sleep, and sexual function in men and women, Brain Research, Volume 1416, 6 October 2011, Pages 80-104.
- [3] York, G. and Kim, Y. "Ultrasound Processing and Computing: Review and Future Directions". Annual Review of Biomedical Engineering, vol.1, no.1, pp.559-581, 1999.
- [4] Mahmood, N. H., Ahmmad, S. N. Z., Hashim, H. and Abdull-Rani, S. N. N. "Ovary Ultrasound Image Edge Detection Analysis: A Tutorial using MATLAB". International Journal of Engineering Research and Applications (IJERA), vol. 2, no. 3, pp.1635-1642, 2012.
- [5] York, G. and Kim, Y. "Ultrasound Processing and Computing: Review and Future Directions". Annual Review of Biomedical Engineering, vol.1, no.1, pp.559-581, 1999.
- [6] Mahmood, N. H., Ahmmad, S. N. Z., Hashim, H. and Abdull-Rani, S. N. N. "Ovary Ultrasound Image Edge Detection Analysis: A Tutorial using MATLAB". International Journal of Engineering Research and Applications (IJERA), vol. 2, no. 3, pp.1635-1642, 2012.
- [7] Vause, T. D. R., Ottawa O. N., Cheung, A. P. and Vancouver, B. C. "Ovulation Induction in Polycystic Ovary Syndrome". Journal of ObstetGynaecolCan, vol. 32, no. 5, pp.495-502, 2010.
- [8] Ultrasound images of the Ovary. Retrieved from www.ultrasoundpaedia.com; www.ultrasoundimages.com; www.sonoworld.com, 20th, March 2015.
- [9] Hamid, B. A. Image texture analysis of transvaginal ultrasound in monitoring ovarian cancer (Doctoral dissertation, School of Engineering, Cardiff University), pp.57-69, 2011.
- [10] Bian, N., Eramian, M. G., and Pierson, R. A. "Evaluation of Texture Features for Analysis of Ovarian Follicular development". Med Image Comput Comput Assist Interv, pp.1-11, 2011.
- [11] Vause, T. D. R., Ottawa O. N., Cheung, A. P. and Vancouver, B. C. "Ovulation Induction in Polycystic Ovary Syndrome". Journal of ObstetGynaecolCan, vol. 32, no. 5, pp.495-502, 2010.
- [12] Hamid, B. A. Image texture analysis of transvaginal ultrasound in monitoring ovarian cancer (Doctoral dissertation, School of Engineering, Cardiff University), pp.57-69, 2011.
- [13] Bian, N., Eramian, M. G., and Pierson, R. A. "Evaluation of Texture Features for Analysis of Ovarian Follicular development". Med Image Comput Comput Assist Interv, pp.1-11, 2011.