International Journal of Basic and Applied Sciences, 14 (5) (2025) 236-239

International Journal of Basic and Applied Sciences

Website: www.sciencepubco.com/index.php/IJBAS
https://doi.org/10.14419/9kskdt54
Research paper



Conservative Approach in An Intra-Articular PIP Joint Fracture Dislocation: A Clinical Case Report

Dr. Urva Dholu, Dr. Swaroop Solunke, Dr. Ashwin Deshmukh, Dr. Amit Patil *

Dr. D. Y. Patil Medical College, Hospital and Research Centre,
Dr. D. Y. Patil Vidyapeeth (Deemed to be University), Pune, India
**Corresponding author E-mail: amit.patil@dpu.edu.in*

Received: July 23, 2025, Accepted: August 30, 2025, Published: September 8, 2025

Abstract

We report the case of a 25-year-old male who sustained an intra-articular fracture-dislocation of the proximal interphalangeal (PIP) joint of the ring finger during a cricket match. Despite being advised of surgical fixation, the patient opted for non-operative management. The fracture was treated using a dorsal extension block splint combined with early rehabilitation. Follow-up radiographs and clinical assessments demonstrated excellent joint stability, pain resolution, and full restoration of function. This case illustrates the viability of conservative treatment in select cases of PIP joint injuries, emphasizing appropriate fracture reduction, early mobilization, and a structured rehabilitation protocol.

Keywords: *Intra-Articular Fracture; PIP Joint; Finger Fracture; Dorsal Extension Block Splinting; PIP Joint Rehabilitation.*

1. Introduction

The proximal interphalangeal (PIP) joint plays a crucial role in finger function and dexterity. As a hinge joint, it is highly vulnerable to injury, particularly in athletes and manual laborers. Fractures of the base of the middle phalanx that involve the articular surface can lead to joint incongruity, instability, stiffness, or post-traumatic arthritis if not addressed promptly and adequately.(Ouellette & Freeland, 1996) Fracture-dislocations of the PIP joint are usually the result of an axial load applied to a partially flexed finger. The management goals are to restore joint congruency, maintain stability, and allow early motion. Involvement of more than 30%–50% of the articular surface traditionally pushes the treatment toward surgical options; however, there is increasing evidence that conservative treatment, when properly executed, can offer comparable results in stable and reducible cases.(Kiefhaber & Stern, 1998)

2. Case Presentation

A 25-year-old right-hand-dominant male cricketer presented with pain and deformity in the right ring finger following impact from a cricket ball 10 days prior. He had received first aid locally and presented to our clinic due to persistent pain and swelling. Examination revealed edema, tenderness over the PIP joint, and a restricted range of motion. Neurovascular examination was normal.
Radiographs demonstrated a dorsal fracture-dislocation at the PIP joint, with a dorsal lip fracture involving approximately 30–35% of the articular surface (Fig. 1A). After detailed counseling about treatment options, the patient declined surgery due to personal reasons.
Under digital block anesthesia (2% lignocaine), closed reduction was performed and maintained with a dorsal extension block splint, positioning the joint in 30° of flexion. Post-reduction radiographs showed concentric joint alignment without subluxation, along with restoration of joint congruency (Fig. 1B). The splint was continued for three weeks.

Copyright © Dr. Urva Dholu et al. This is an open access article distributed under the Creative Commons Attribution License, which permits unrestricted use, distribution, and reproduction in any medium, provided the original work is properly cited.

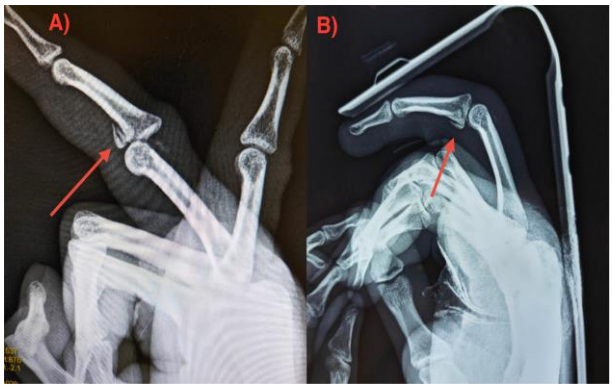

Fig. 1: Radiographs of A 25-Year-Old Male with Right Ring Finger Injury.

(A) Pre-reduction radiograph showing intra-articular fracture of the base of the middle phalanx with dorsal fracture-dislocation involving 30–35% of articular surface.
(B) Post-reduction radiograph showing restored joint congruency and concentric reduction stabilized with dorsal extension block splint.
During follow-up, radiographs confirmed maintained reduction and early callus formation consistent with healing. At three weeks, the splint was removed, and a physiotherapy regimen was initiated focusing on controlled range-of-motion exercises, differential tendon gliding, edema management, and passive joint mobilization.
By the sixth week, the patient demonstrated a near-complete active range of motion with no instability, and radiographic evidence of joint stability was observed (Fig. 2). A home-based exercise plan was reinforced. At one-year follow-up, the patient had pain-free full flexion-extension of the PIP joint with no radiographic evidence of degenerative changes.



Fig. 2: Radiograph at 6 Weeks Follow-Up Showing Maintained Reduction, Stable PIP Joint, and Early Signs of Fracture Healing.

2.1. Rehabilitation Protocol

Timeline	Interventions
Week 1–3	Immobilization in a dorsal extension block splint, elevation, and analgesics
Week 3–6	Active-assisted ROM, differential tendon gliding (FDS/FDP), PIP/DIP mobilization, edema control
Week 6 onwards	Full active ROM, strengthening with putty/resistance bands, sports-specific grip exercises

Supervised physiotherapy was done thrice weekly, supplemented by home exercises twice daily.

3. Discussion

Conservative management of intra-articular PIP fractures remains controversial due to risks of stiffness and post-traumatic arthritis. However, it is increasingly supported for fractures with <40% articular involvement and when concentric reduction is maintained.(Mehta & Phillips, 2005)
Dorsal extension block splinting, introduced by Eaton, offers a balance between immobilization and early movement. It prevents dorsal subluxation and extensor mechanism adhesions (Freiberg, 2007). Studies have shown up to 85% good-to-excellent outcomes in well-selected patients treated conservatively (Hamer & Quinton, 1992).
Comparatively, surgical options such as extension-block pinning or open reduction with internal fixation are often recommended for unstable or comminuted injuries. Calfee et al. (2008) reported favorable outcomes with extension-block pinning but also noted complication risks, such as stiffness and hardware irritation. Recent studies support individualized decision-making, with some evidence suggesting that younger, compliant patients with low comminution may achieve outcomes equivalent to surgical cases (Deitch et al., 1999; Elfar & Mann, 2013). In contrast, our case demonstrates that when stability is achieved nonoperatively, conservative management with early rehabilitation may achieve equally satisfactory outcomes.
A critical determinant of success is early mobilization, ideally within 2–3 weeks, which prevents contracture and enhances tendon gliding(Kiefhaber & Stern, 1998). In this case, adherence to physiotherapy and timely initiation of motion minimized stiffness and avoided extensor lag.

Potential complications of PIP injuries include residual joint stiffness, extensor lag, post-traumatic arthritis, and malunion. Our patient avoided these due to stable reduction, structured rehabilitation, and strong compliance.
Factors favoring conservative management include:

- Low comminution
- <40% articular involvement
- Stable post-reduction alignment
- High patient compliance

Generalizability & Future Directions
The limitation of this report is its single-patient design. Larger cohort studies and multi-center trials are needed to validate the effectiveness of conservative treatment across broader patient populations. Variables such as age, occupation, injury mechanism, and compliance should be evaluated as predictors of success. Future research should also address optimal splinting duration, thresholds for surgical intervention, and long-term outcomes.

3.1. Clinical Milestones

Milestone	Timeline
Splinting duration	3 weeks in a dorsal extension block splint
Initiation of physiotherapy	Week 3 (active-assisted ROM, tendon gliding)
Near-complete ROM	Week 6
Full ROM and sports return	1-year follow-up

3.2. Cost-Effectiveness

Conservative management may also provide economic advantages, particularly in low-resource settings, by avoiding surgical costs, anesthesia risks, and prolonged hospital stays. Mehta and Phillips (2005) highlighted the practicality of well-supervised nonoperative care, which aligns with our findings.

4. Conclusion

Intra-articular PIP joint fracture-dislocations are challenging due to the intricate interplay between stability and mobility. Surgical intervention is often recommended, especially in complex or unstable cases. However, as demonstrated in this report, conservative management using dorsal extension block splinting combined with structured early rehabilitation can yield excellent outcomes in carefully selected patients. This approach highlights the importance of individualized care, patient compliance, and the role of physiotherapy in achieving functional recovery.

5. Conflict of Interest

The authors declare no conflict of interest related to the publication of this case report.

6. Financial Support

No financial support or sponsorship was received for this study.

7. Use of AI

Artificial intelligence was used in a limited capacity to assist with grammar refinement and formatting. All scientific content, clinical interpretation, and conclusions were generated and reviewed solely by the authors.

8. Ethical Approval

This case report was conducted in accordance with the ethical principles outlined in the Declaration of Helsinki. Institutional ethical approval was not required for a single case report.

9. Consent

Written informed consent was obtained from the patient for the publication of clinical details and images in this case report. Efforts have been made to ensure patient anonymity, and no identifiable personal information is included.

References

[1] Calfee, R. P., & Sommerkamp, T. G. (2009). Fracture–Dislocation About the Finger Joints. The Journal of Hand Surgery, 34(6), 1140–1147. https://doi.org/10.1016/j.jhsa.2009.04.023.
[2] Deitch, M. A., Kiefhaber, T. R., Comisar, B. R., & Stern, P. J. (1999). Dorsal fracture dislocations of the proximal interphalangeal joint: Surgical complications and long-term results. The Journal of Hand Surgery, 24(5), 914–923. https://doi.org/10.1053/jhsu.1999.0914.
[3] Elfar, J., & Mann, T. (2013). Fracture-dislocations of the proximal interphalangeal joint. The Journal of the American Academy of Orthopaedic Surgeons, 21(2), 88–98. https://doi.org/10.5435/JAAOS-21-02-88.

[4] Freiberg, A. (2007). Management of proximal interphalangeal joint injuries. Canadian Journal of Plastic Surgery, 15(4), 199–203. https://doi.org/10.1177/229255030701500407.
[5] Hamer, D. W., & Quinton, D. N. (1992). Dorsal Fracture Subluxation of the Proximal Interphalangeal Joints Treated by Extension Block Splintage. Journal of Hand Surgery, 17(5), 586–590. https://doi.org/10.1016/S0266-7681(05)80249-9.
[6] Kiefhaber, T. R., & Stern, P. J. (1998). Fracture dislocations of the proximal interphalangeal joint. The Journal of Hand Surgery, 23(3), 368–380. https://doi.org/10.1016/S0363-5023(05)80454-X.
[7] Mehta, V., & Phillips, C. S. (2005). Flexor Tendon Pulley Reconstruction. Hand Clinics, 21(2), 245–251. https://doi.org/10.1016/j.hcl.2004.12.002.
[8] Ouellette, E. A., & Freeland, A. E. (1996). Use of the Minicondylar Plate in Metacarpal and Phalangeal Fractures: Clinical Orthopaedics and Related Research, 327, 38–46. https://doi.org/10.1097/00003086-199606000-00007.